

MIKROSKOPISK SPOTGUIDE

4. semester bachelor medicin KU

LEGAL NOTICE!
Dette materiale er udviklet af ansatte ved Københavns Universitet. Det stilles alene til rådighed for brugerne som studie- eller forskningsmateriale i KU regi. Materialet er copyright beskyttet og må IKKE anvendes i forbindelse med løsning af opgaver udenfor KU, hverken til kommercielt eller ikke-kommercielt brug.



2. udgave, Forår 2014

Illustrationer hentet fra Sundhedsvidenskabelige Fakultets service VIRMIK https://virmik3.sund.ku.dk/content.aspx

Lavet af Anders Gullach, Martin Iversen og Mathias Heitmann.

Forlagt og grafisk tilrettelagt af Mathias Heitmann.

Tak til alle 4. semesters Anatomiundervisere for faglig korrekturlæsning: Martin Iversen, Anders Gullach, Nicolaj Laugesen, Gitte Pedersen og Hannelouise Kissow.

I samarbejde med lektor Steen Seier Poulsen.

Indholdsfortegnelse

Mundhulen

1. Labium oris 5
2. Lingua 6
2A. Pap. filiformes 7
3. Papilla foliata, smagsløg 8
4. Lingua papilla vallata 9
5. Radix Linguae 10
6. Tidlig tandanlæg 11
7. Sen tandanlæg 12
8. Palatum molle 13
9. Tonsilla palatina 14
10. Tonsilla pharyngea 15

Mave-tarmkanalen

11. Esophagus øvre 18
11A. Esophagus midt 19
12. Esophagus nederst 20
13. Fundus ventriculi 21-22
14. Pars pylorica 23
14A. Gastrin immunreaktion 24
15. Pars pylorica og Duodenum 25
16. Duodenum 26
17. Jejunum 27
18. Jejenum 28
19. Appendix vermiformis 29
20. Colon 30

Lever, Galdeveje & Spytkirtler

21. Lever 33
22. Lever med sinusioder 34
24. Glandula parotis 35
25. Glandula submandibularis 36
25A. Glandula submandibularis 37
26. Glandula sublingualis 38
27. Pancreas 39
28. Insulin immunreaktion 40
29. Glucagon immunreaktion 41

Hjertet

36. Valvula Semilunaris “Poseklap” 44
37. Auricula dextra 45
38. Nodus atrioventricularis “AV-knude” 46-48
39. Septum interventricularis 49
39A. Septum interventricularis m. His’ske bundt 50-51

Luftvejene & Lungerne

40. Ala nasi 54
41. Cavum nasi, Regio respiratoria 55
41A. Epiglottis 56
42. Trachea 57
43. Bronchie + Antrakotisk lymfeknude 58
43A. Lunge 59
44. Lunge, rotte perf.fixeret 60
45. Bronchie + Lunge 61

MIKROSKOPISK SPOTGUIDE

Mundhulen



Af Mathias Gierløff Heitmann

1. Læbe, Labium oris

Hæmatoxylin-Eosin

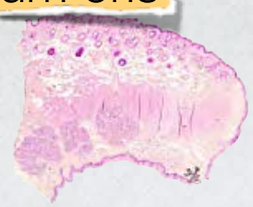

BMI
Præp. 1
Kasse 24

2. Tunge, Lingua

Hæmatoxylin-Eosin

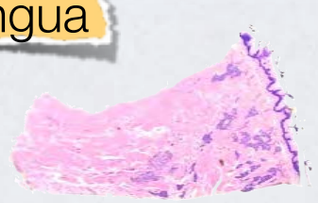

BMI
Præp. 2
Kasse 48

2A. Papillae filiformes

Hæmatoxylin-Eosin



BMI
Præp. nr: 2A
Kasse: 48

3. Papillae foliatae, Smagsløg

Hæmatoxylin-Eosin

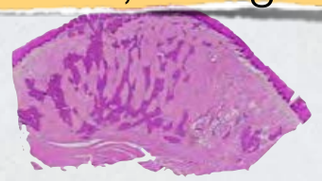

BMI
Præp. 3
Kasse 48

4. Papilla vallata, Smagsløg

Hæmatoxylin-Eosin

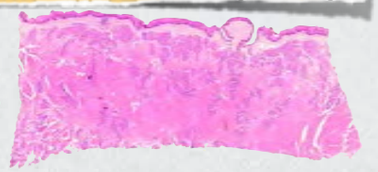

BMI
Præp. 4
Kasse 36

5. Radix linguae

Hæmatoxylin-Eosin

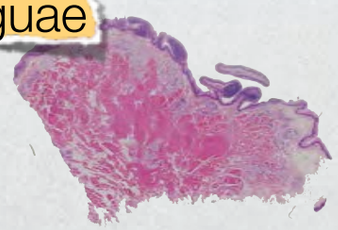

BMI
Præp. 5
Kasse 24

6. Tidligt tandanlæg

Toluidinblå



BMI
Præp. 6
Kasse 48

7. Sent tandanlæg

Toluidinblå

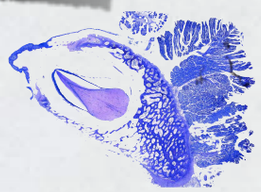

BMI
Præp. 7
Kasse 19

8. Palatum molle

Mallory-Azan

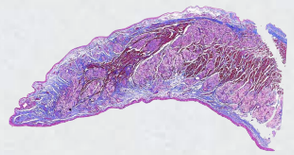

BMI
Præp. 8
Kasse 17

9. Tonsilla palatina

Hæmatoxylin-Eosin

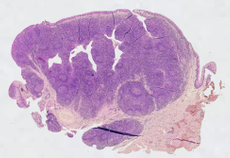

BMI
Præp. 9
Kasse 48

10. Tonsilla Pharyngea

Hæmatoxylin-Eosin



Div 10
Tonsilla
Pharyngea

1. Læbe, Labium oris

Hæmatoxylin-Eosin

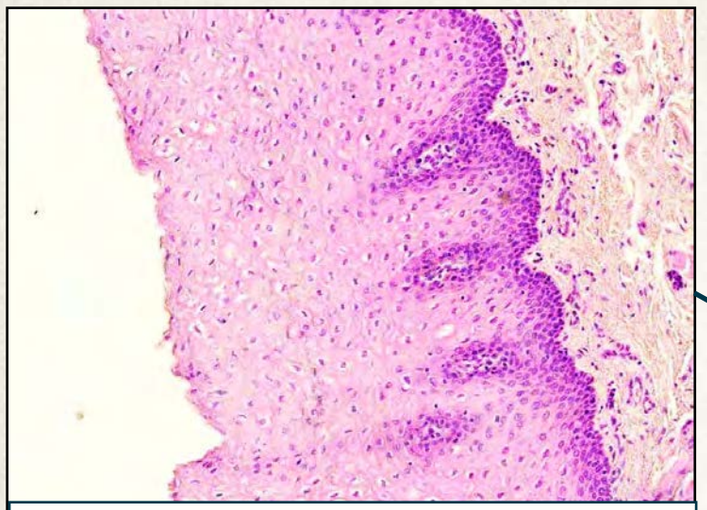

Uforhornet flerlaget pladeepithel

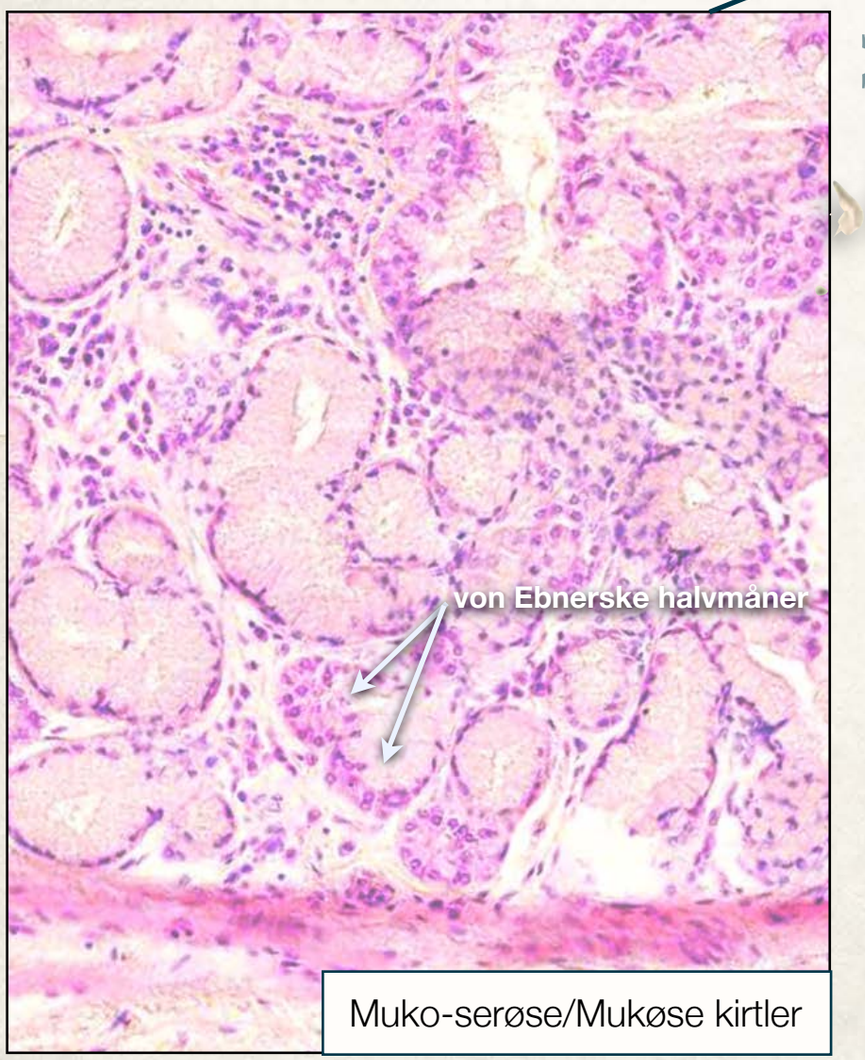

Muko-serøse/Mukøse kirtler

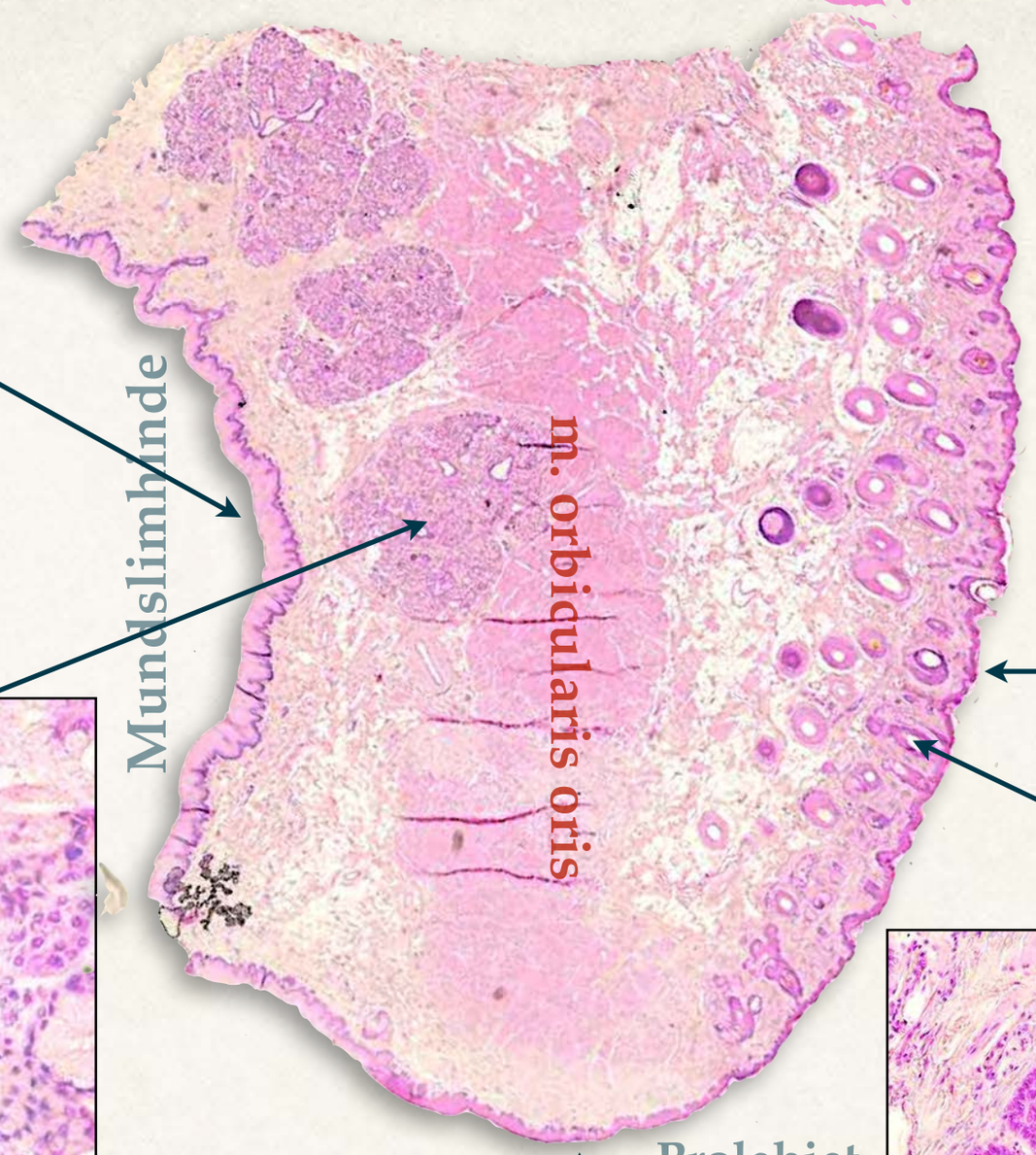

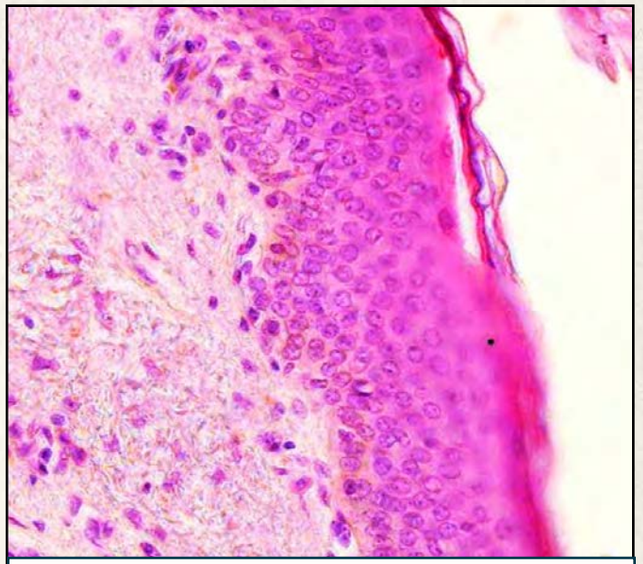

Forhornet flerlaget pladeepithel

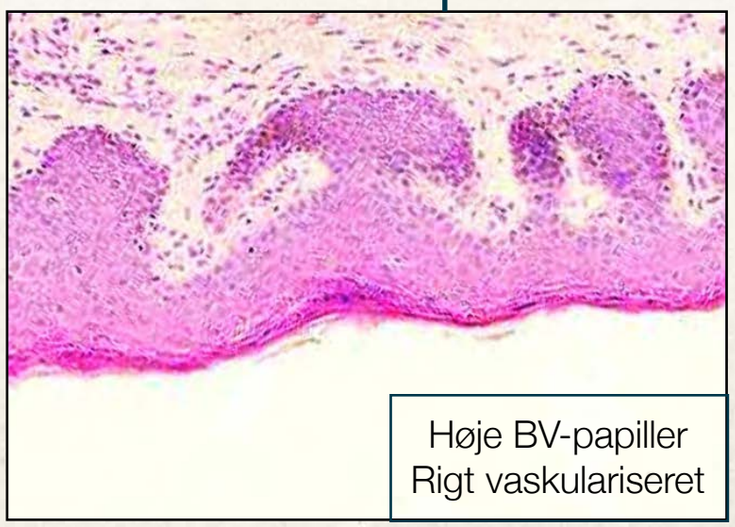

Høje BV-papiller
Rigt vaskulariseret

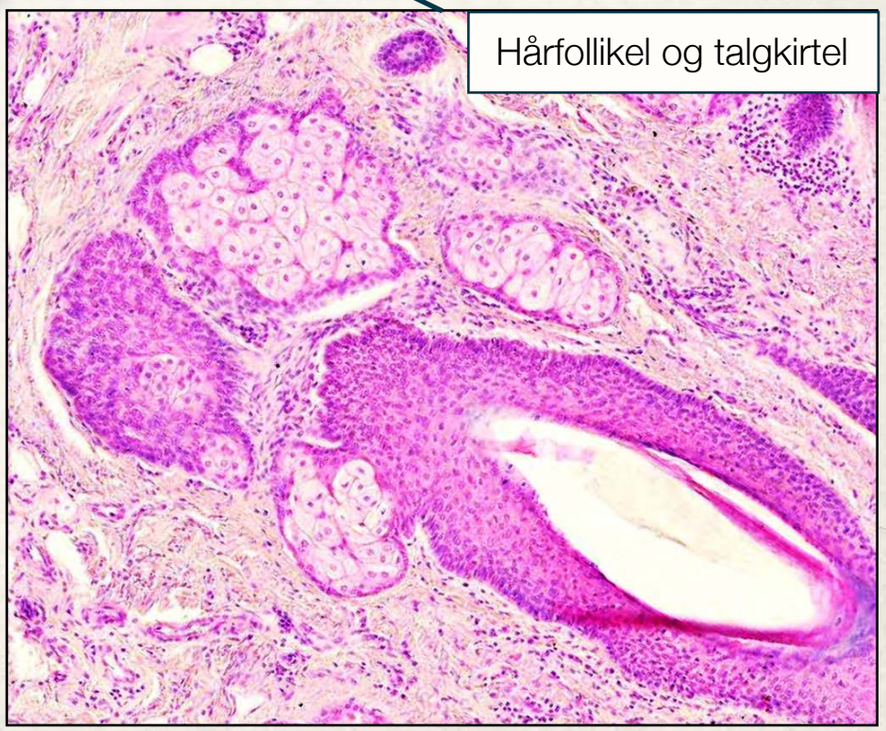

Hårfollikel og talgkirtel

2. Tunge, Lingua

Hæmatoxylin-Eosin

Ødelagt epithel (ingen papillae filiformes)

Dorsum linguae

Aponeurosis linguae

Tværstribet muskulatur

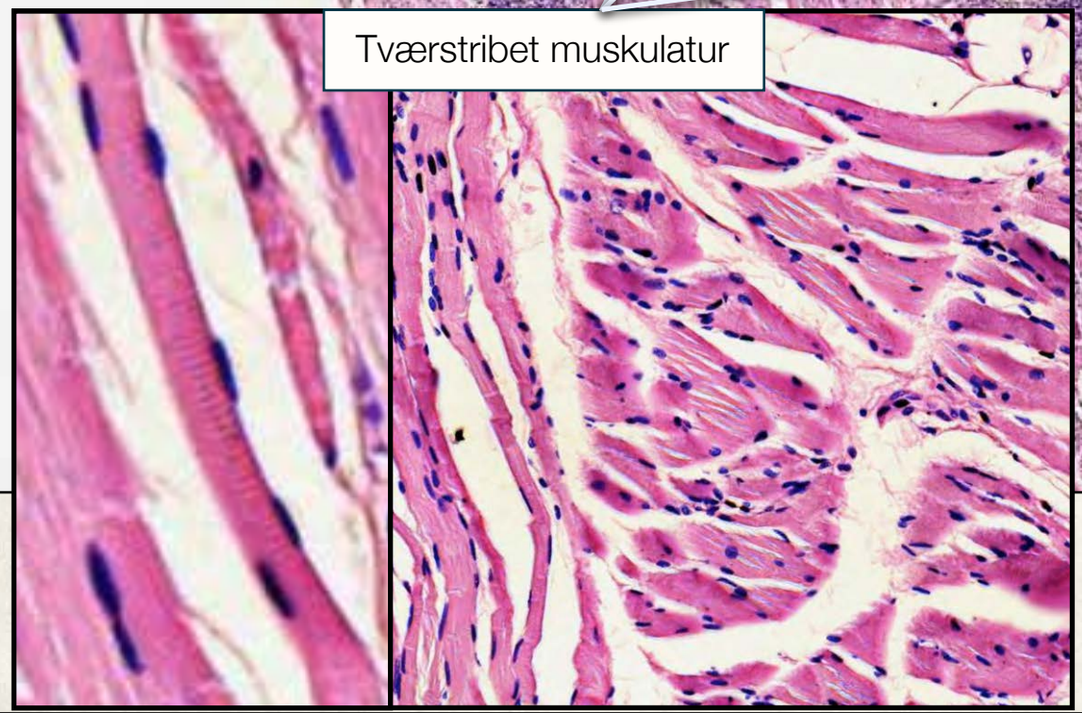

Serøse acini

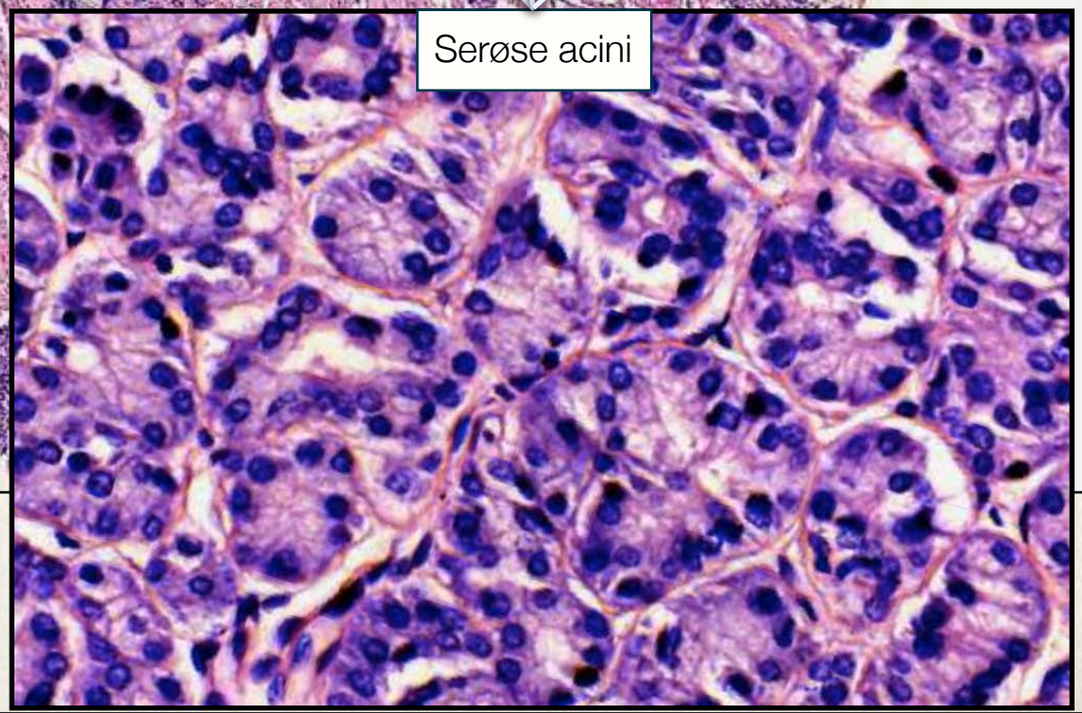

2A. Papillae filiformes

Hæmatoxylin-Eosin

Dorsum linguae

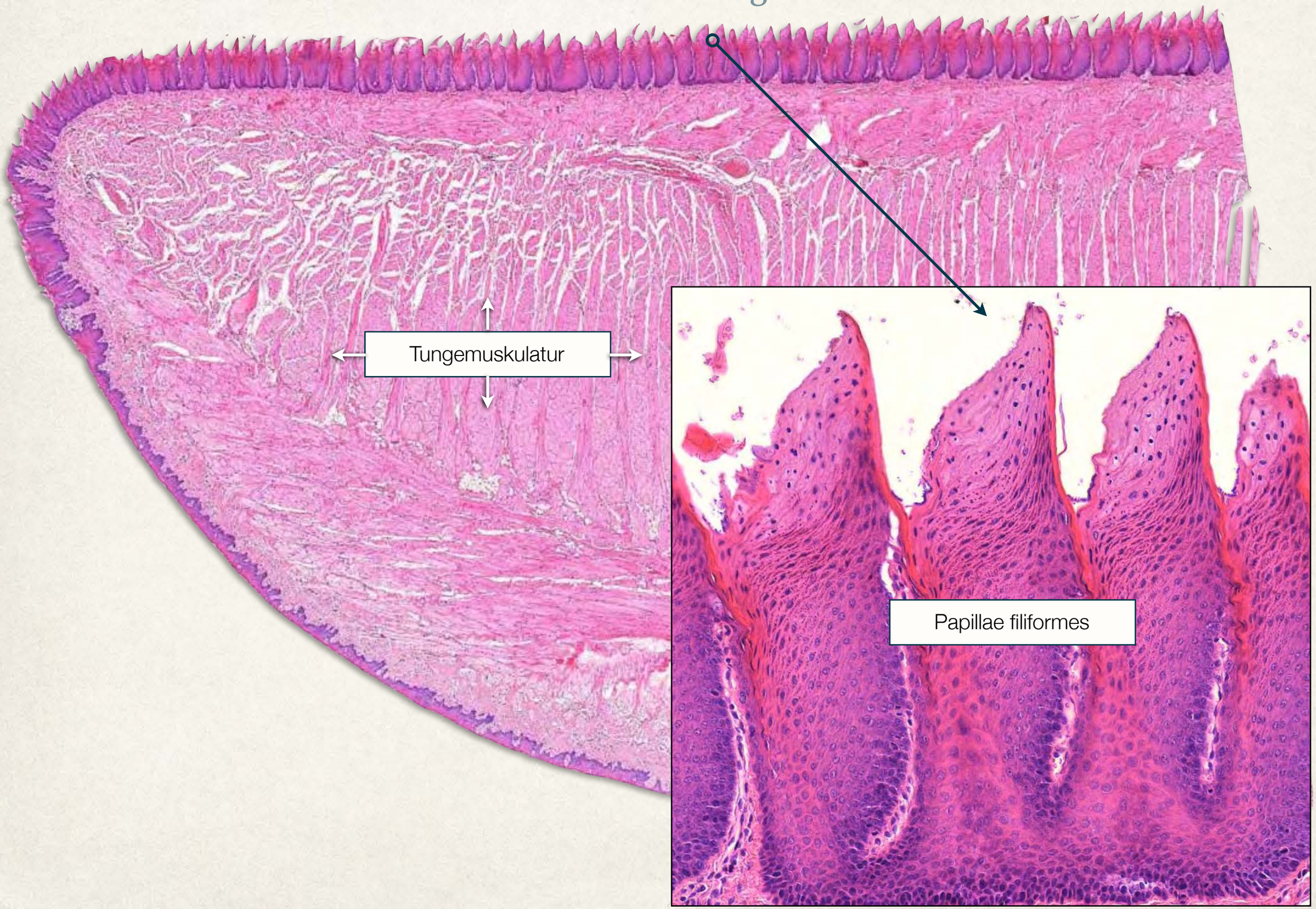

3. Papillae foliatae, Smagsløg

Hæmatoxylin-Eosin

Dorsum linguae



4. Papilla vallata, Smagsløg

Hæmatoxylin-Eosin

Dorsum linguae

Vold

Voldgrav

Papilla (circum)vallata

Smagsløg

von Ebnerske kirtler (serøse) samt udførselsgange

Hæmatoxylin Eosin

5. Radix linguae

= Præparatets afskårne kant

Dorsum linguae

Bælghule

Leukocytinfiltration

Flerlaget pladeepithel

Mukøs acinus

Ansamling af lymfoidt væv i lamina propria

Leukocytter

6. Tidligt tandanlæg

Toluidinblå

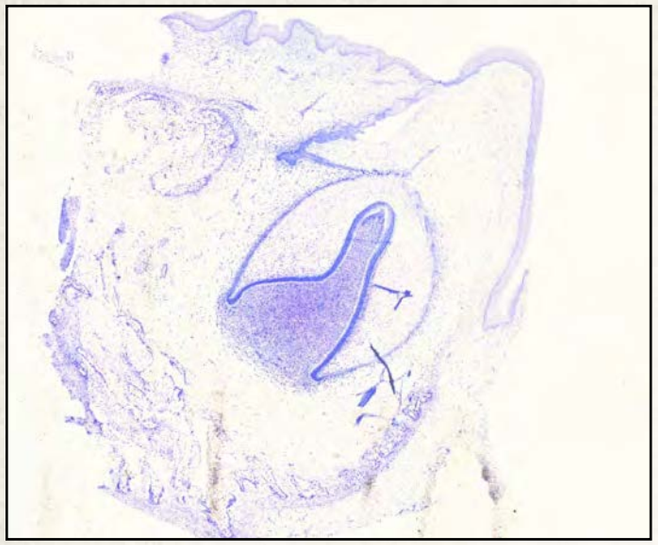

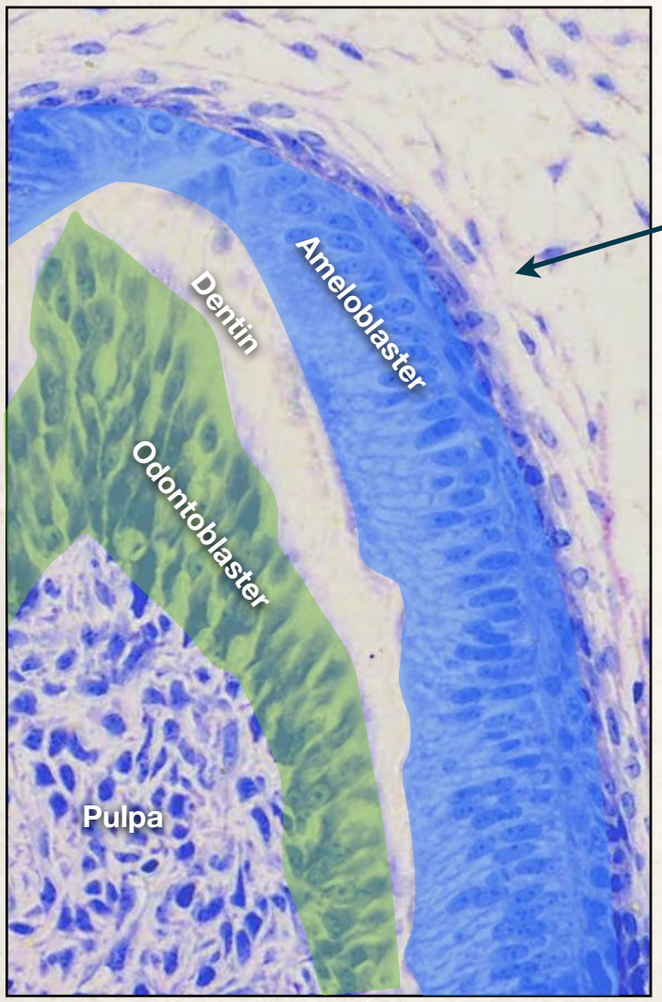

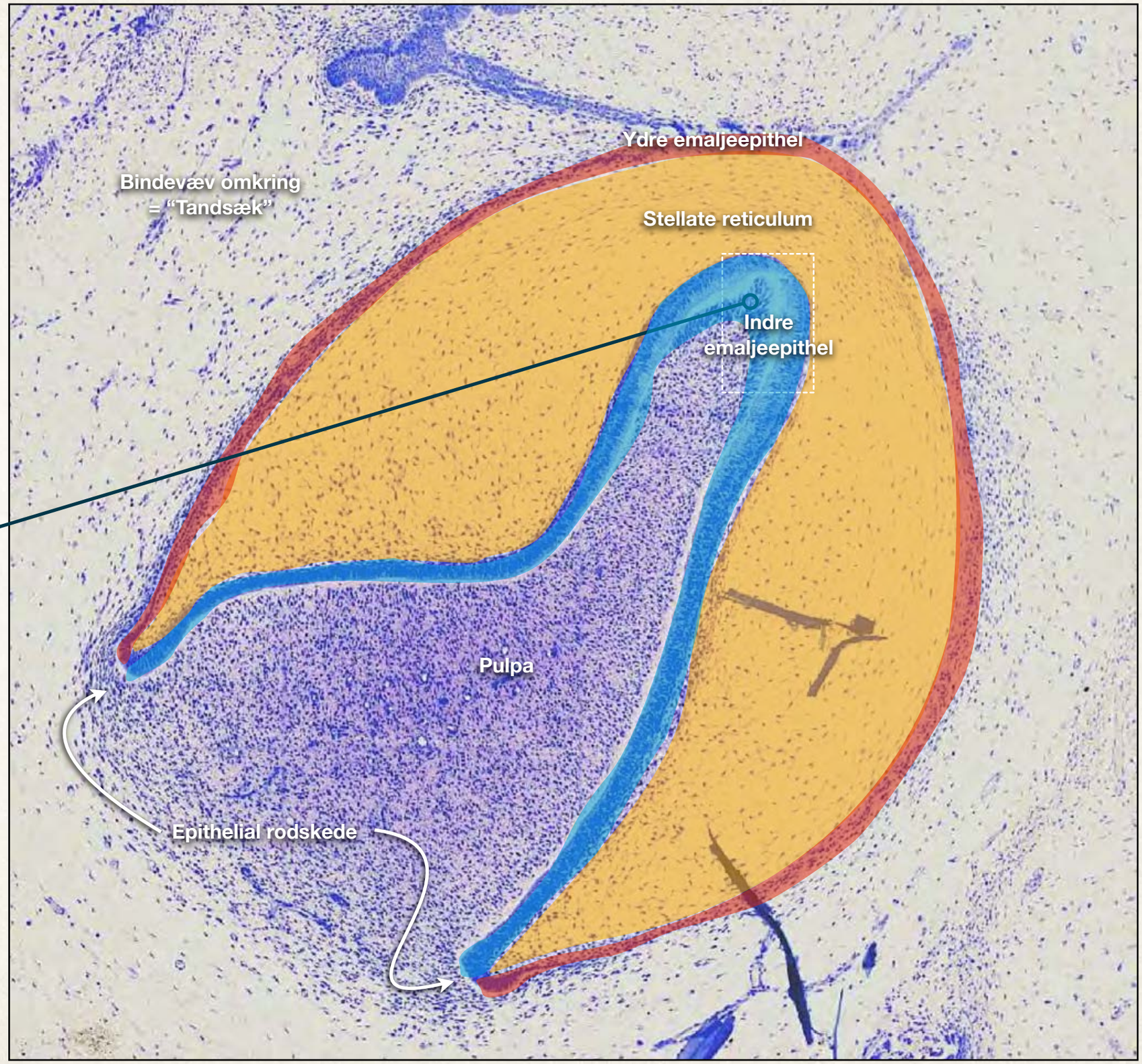

7. Sent tandanlæg

Toluidinblå

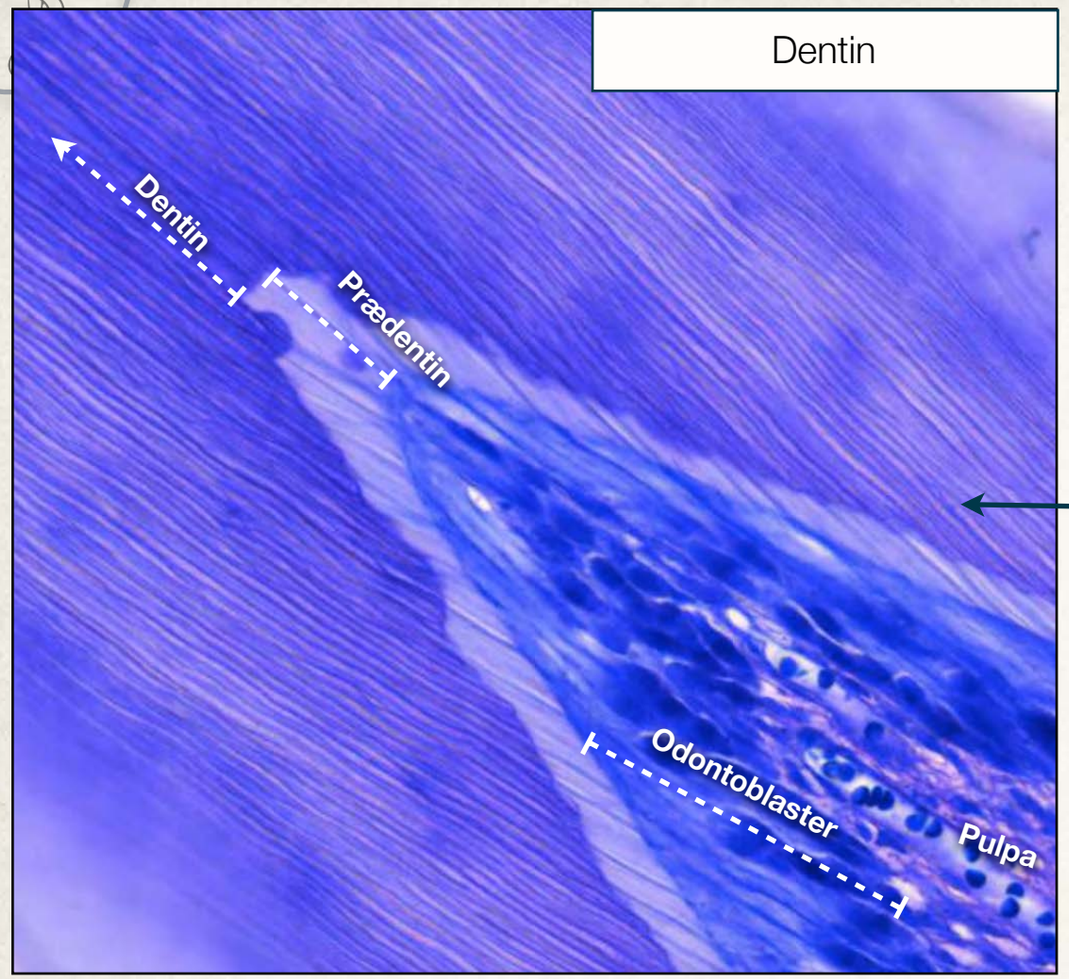

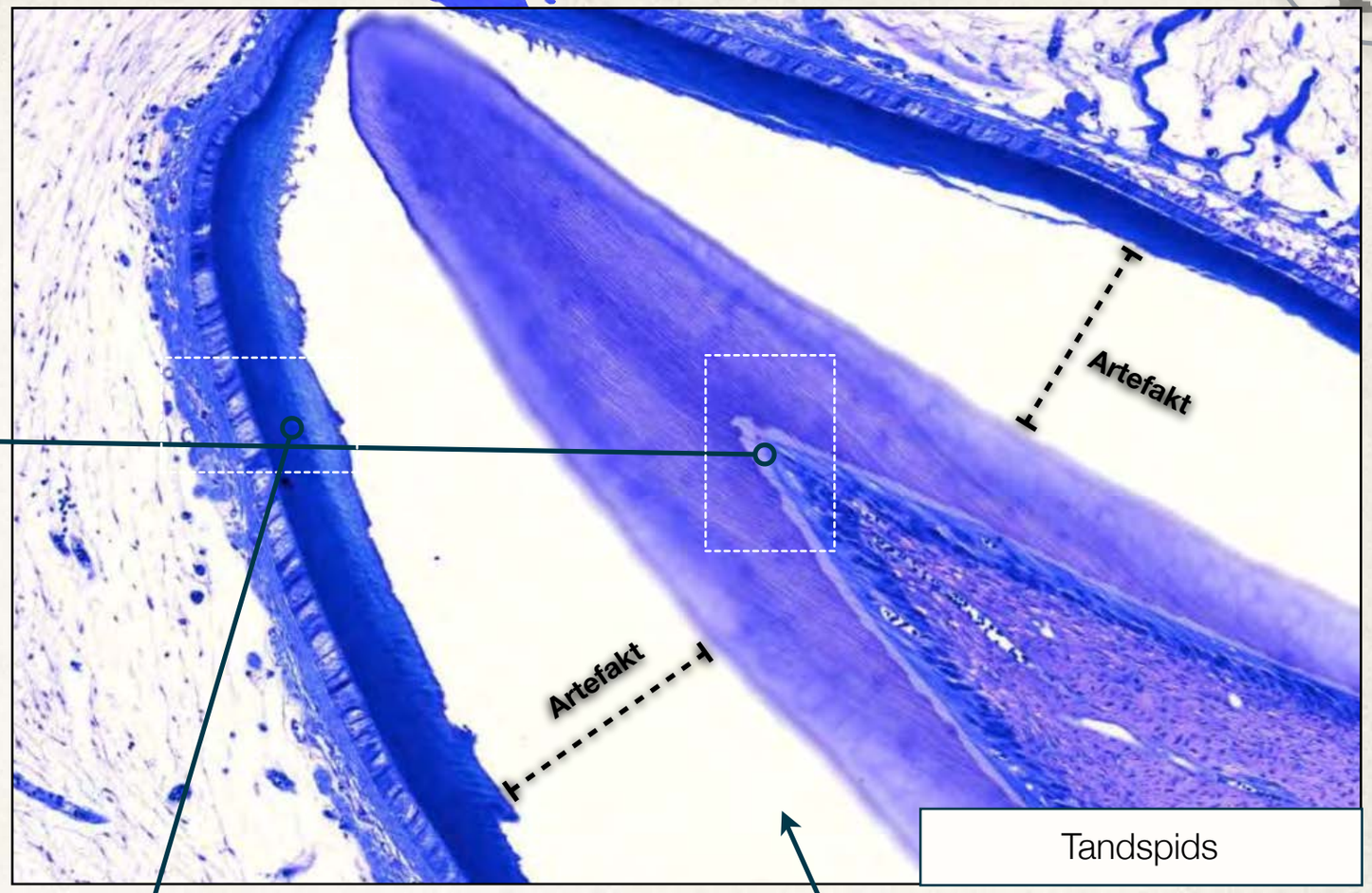

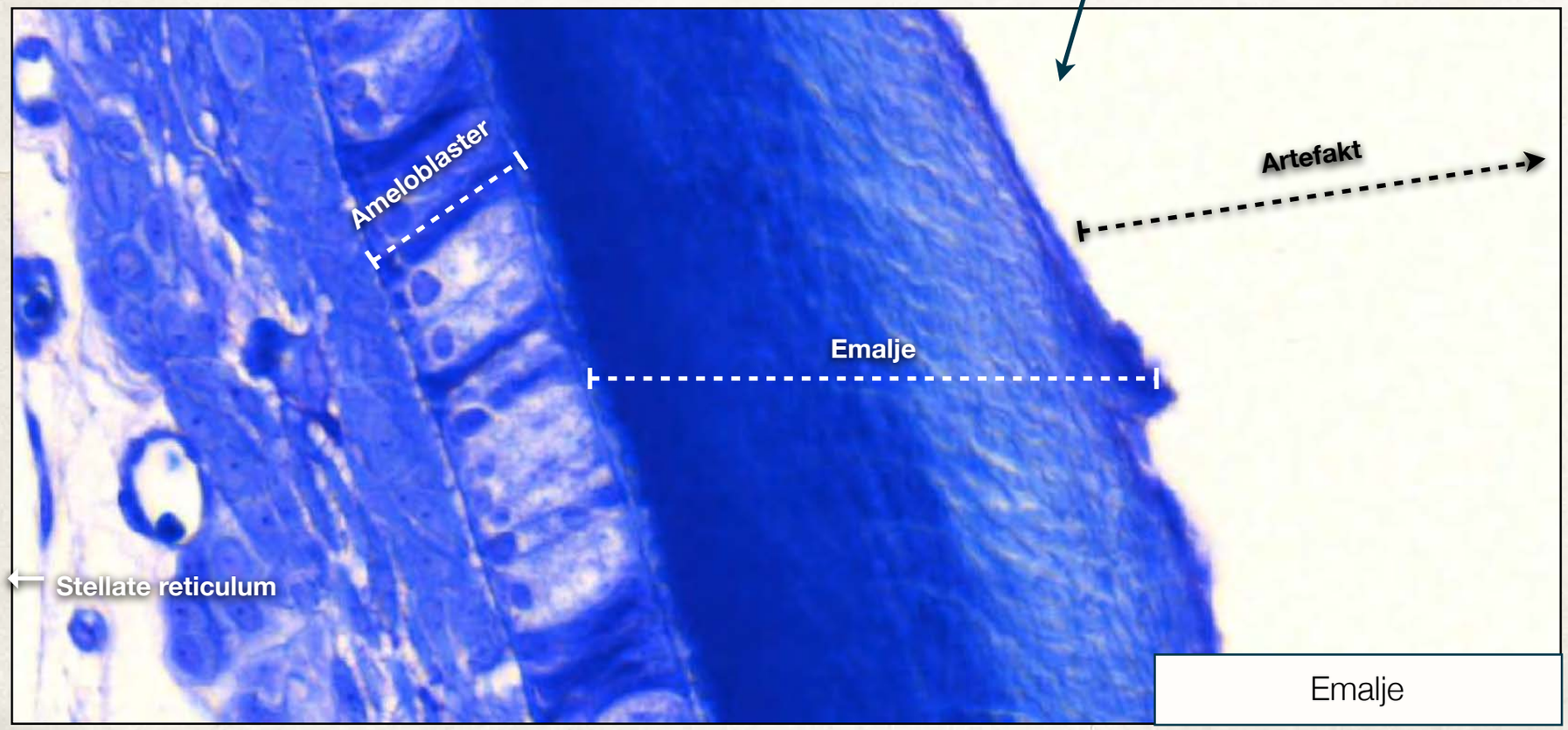

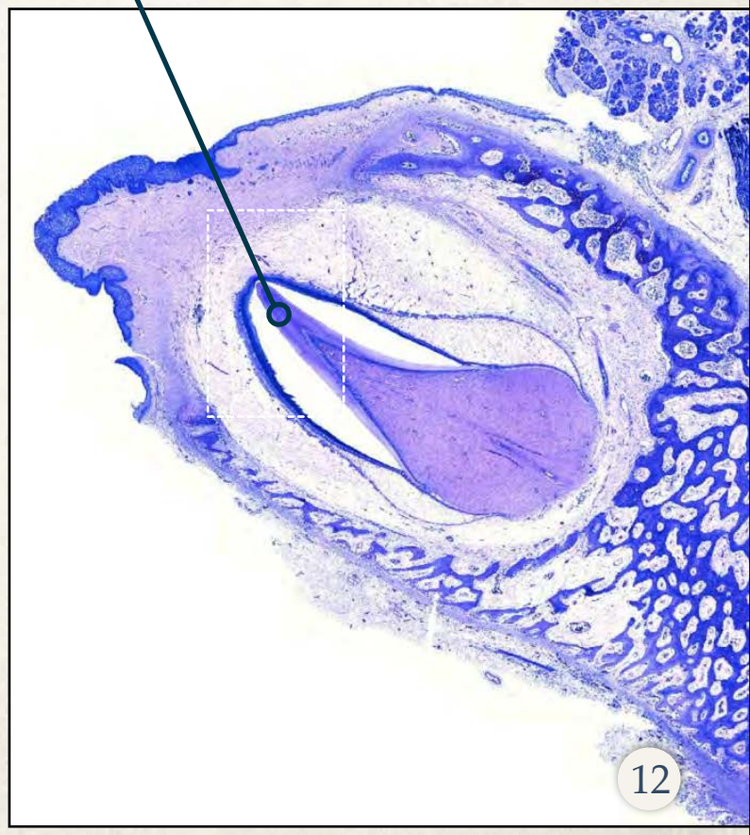

8. Palatum molle

Mallory-Azan

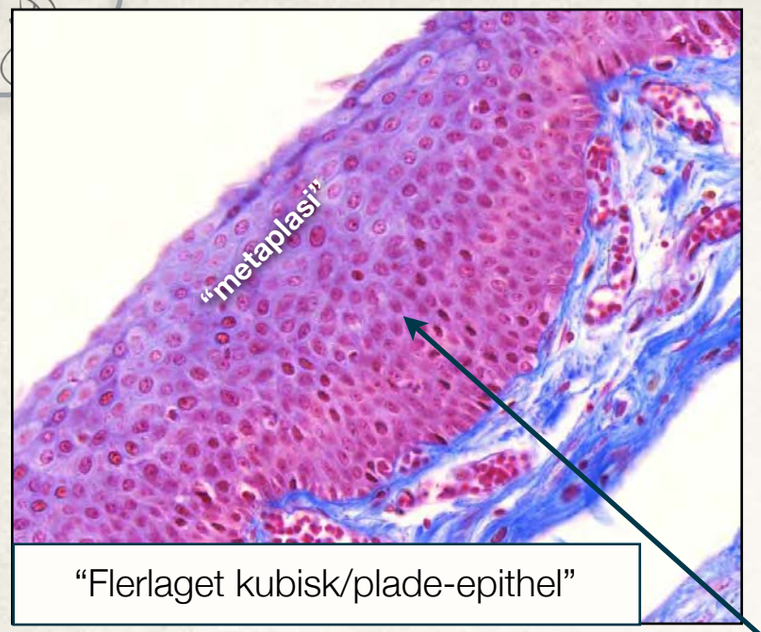

"Flerlaget kubisk/plade-epithel"

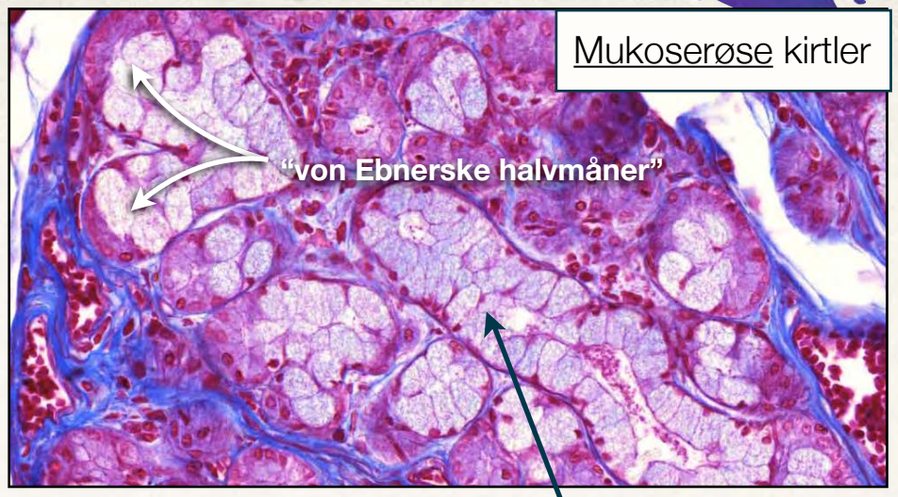

Mukoserøse kirtler

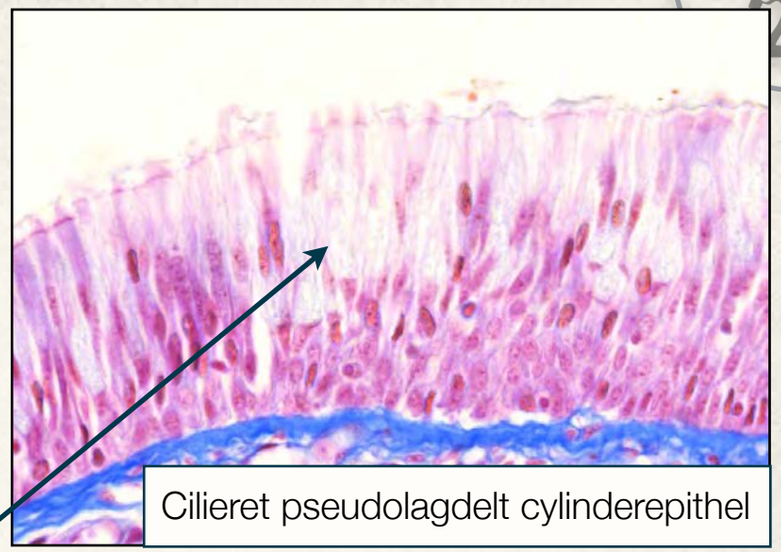

Cilieret pseudolagdelt cylinderepithel

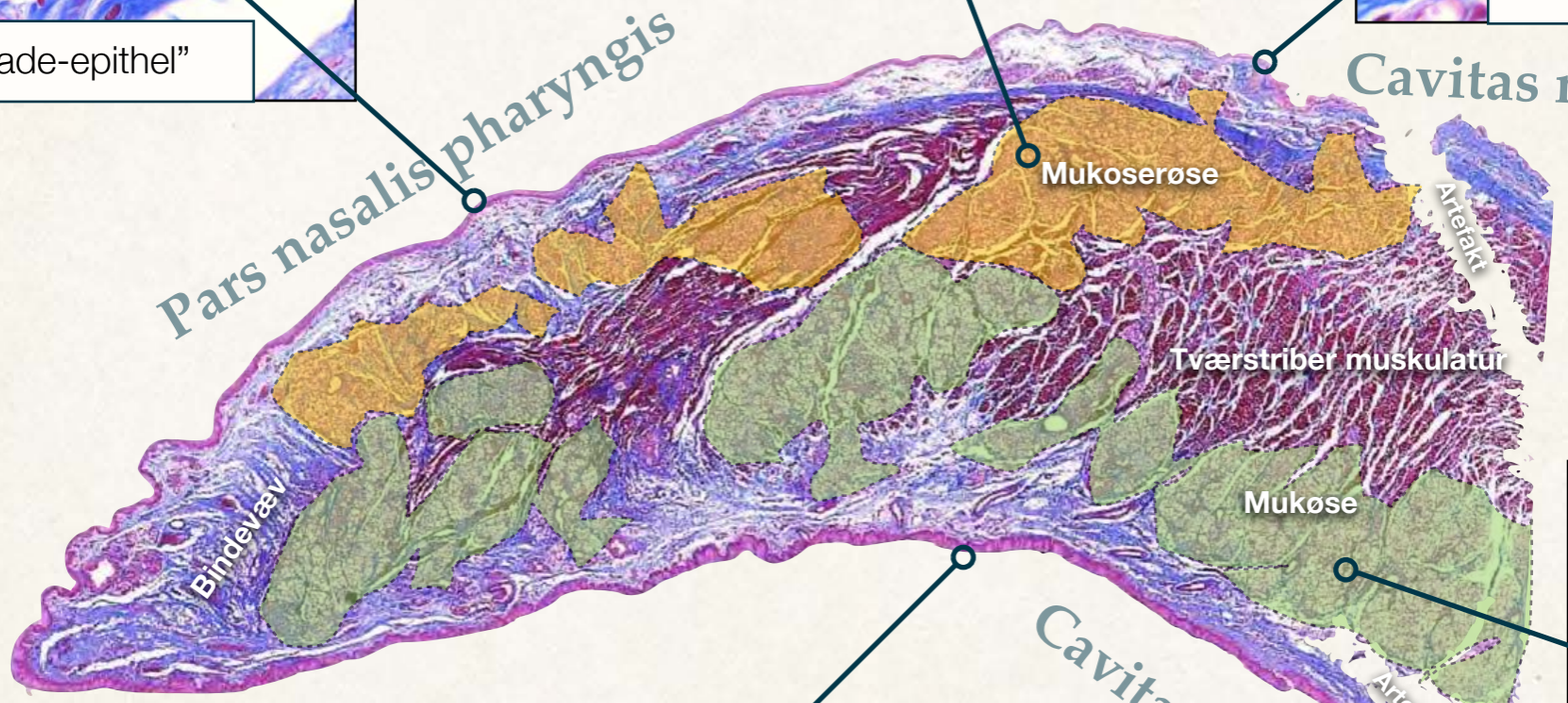



Uforhornet flerlaget pladeepithel

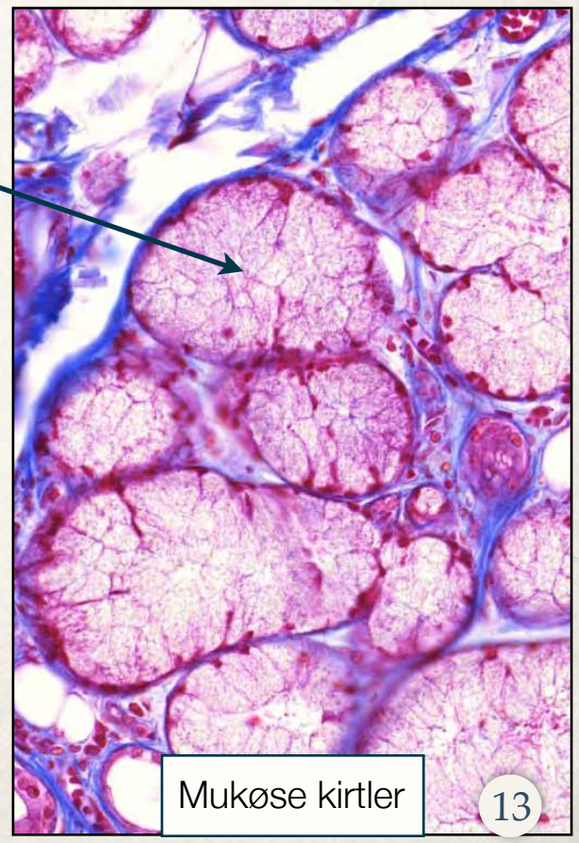

Mukøse kirtler

9. Tonsilla palatina

Hæmatoxylin-Eosin

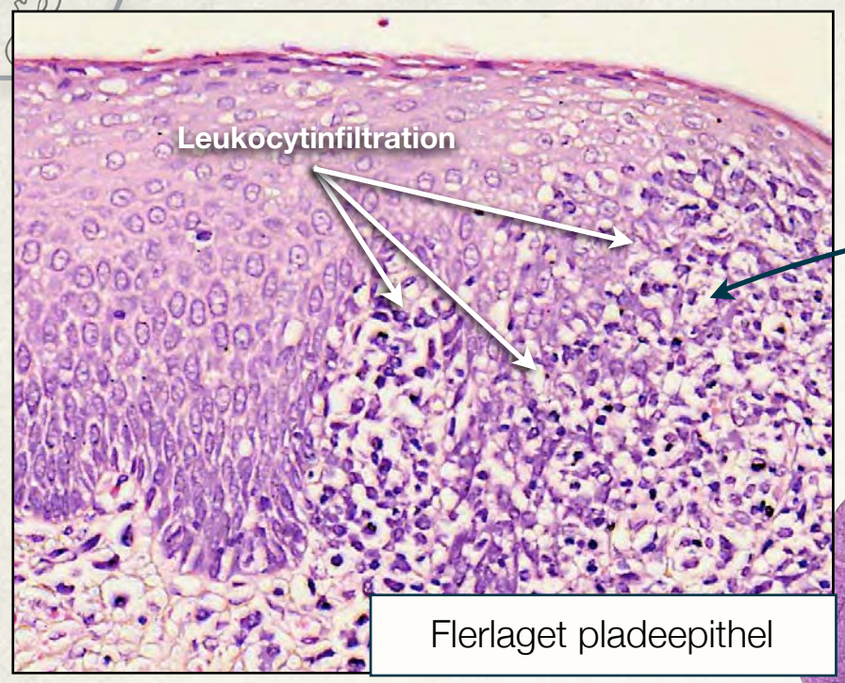

Flerlaget pladeepithel

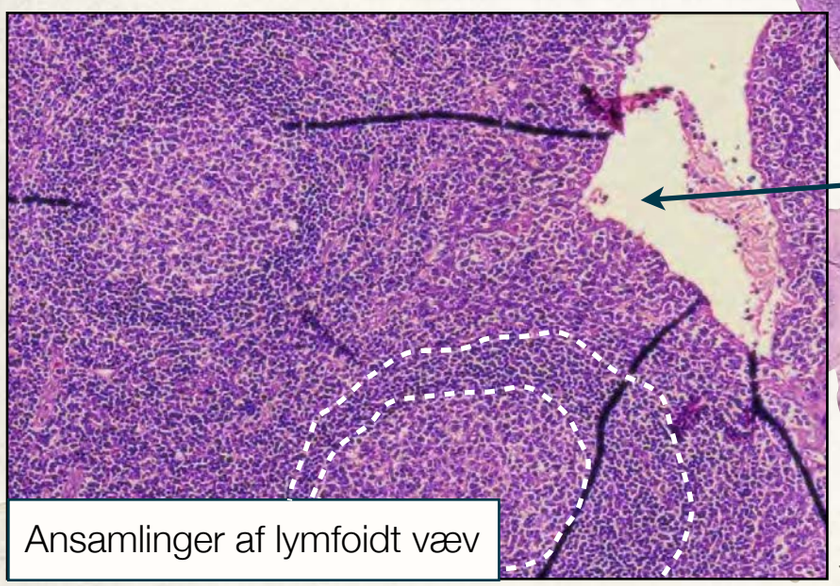

Ansamlinger af lymfoidt væv



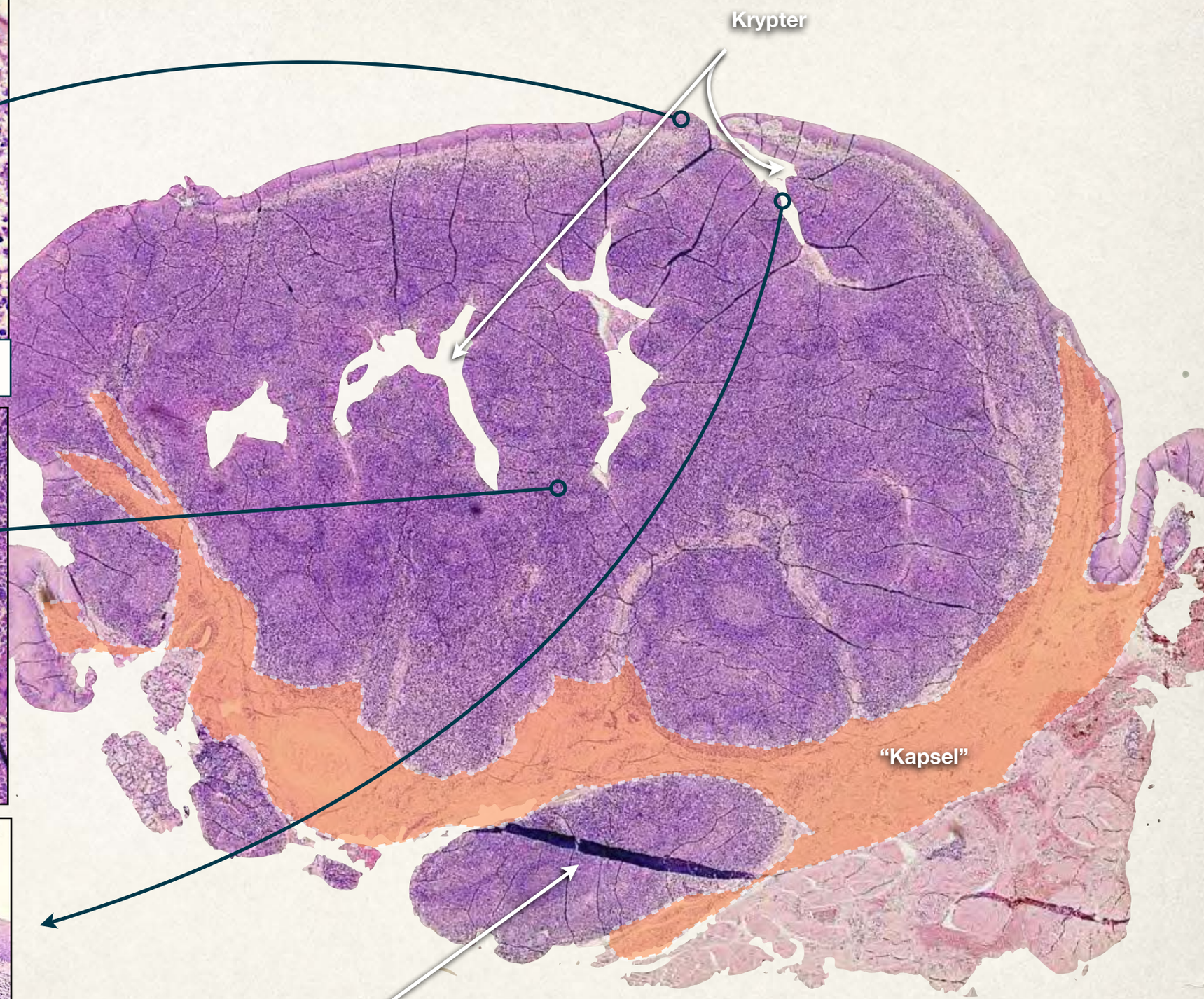

10. Tonsilla Pharyngea

Hæmatoxylin-Eosin



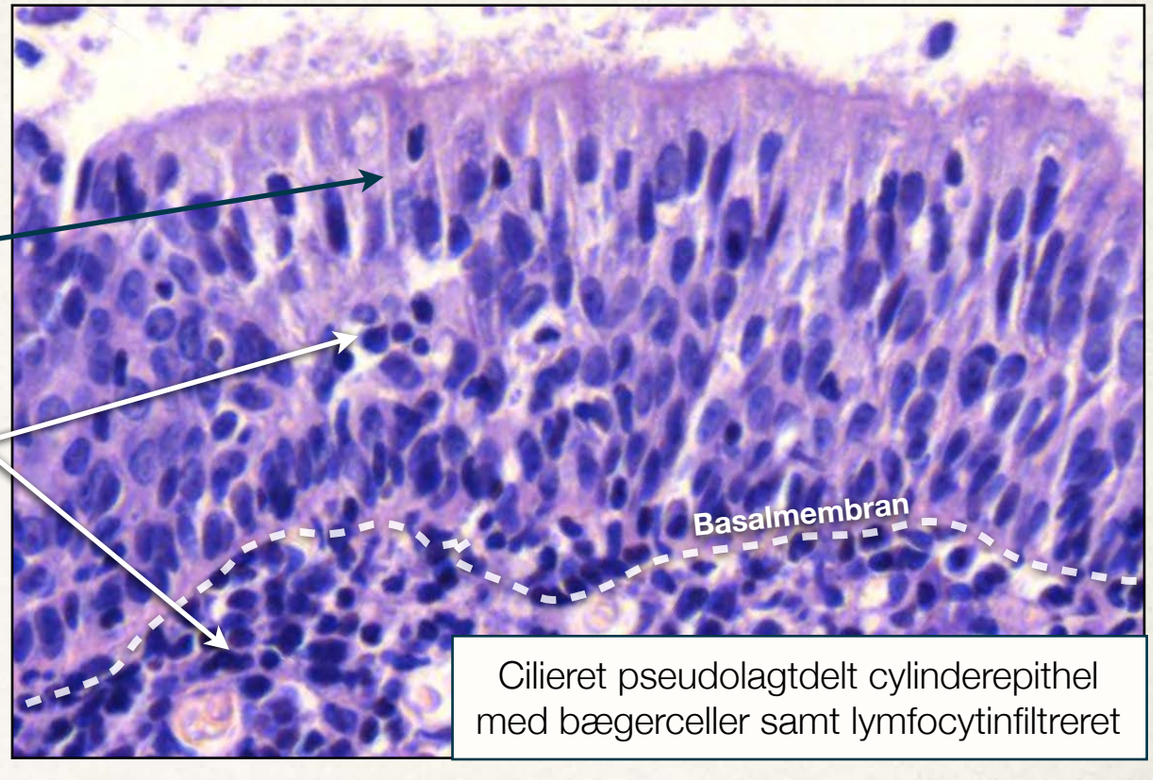

Cilieret pseudolagtdelt cylinderepithel med bægerceller samt lymfocytinfiltreret

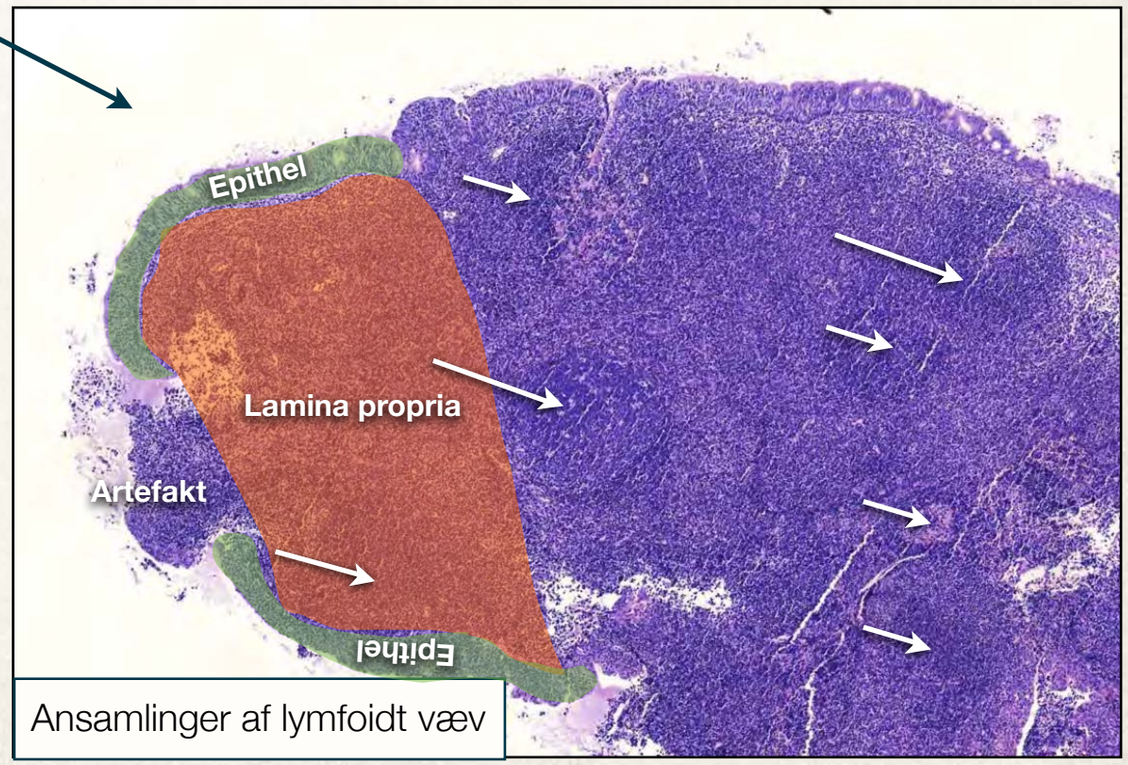

Ansamlinger af lymfoidt væv

MIKROSKOPISK SPOTGUIDE

MAVE-TARMKANALEN

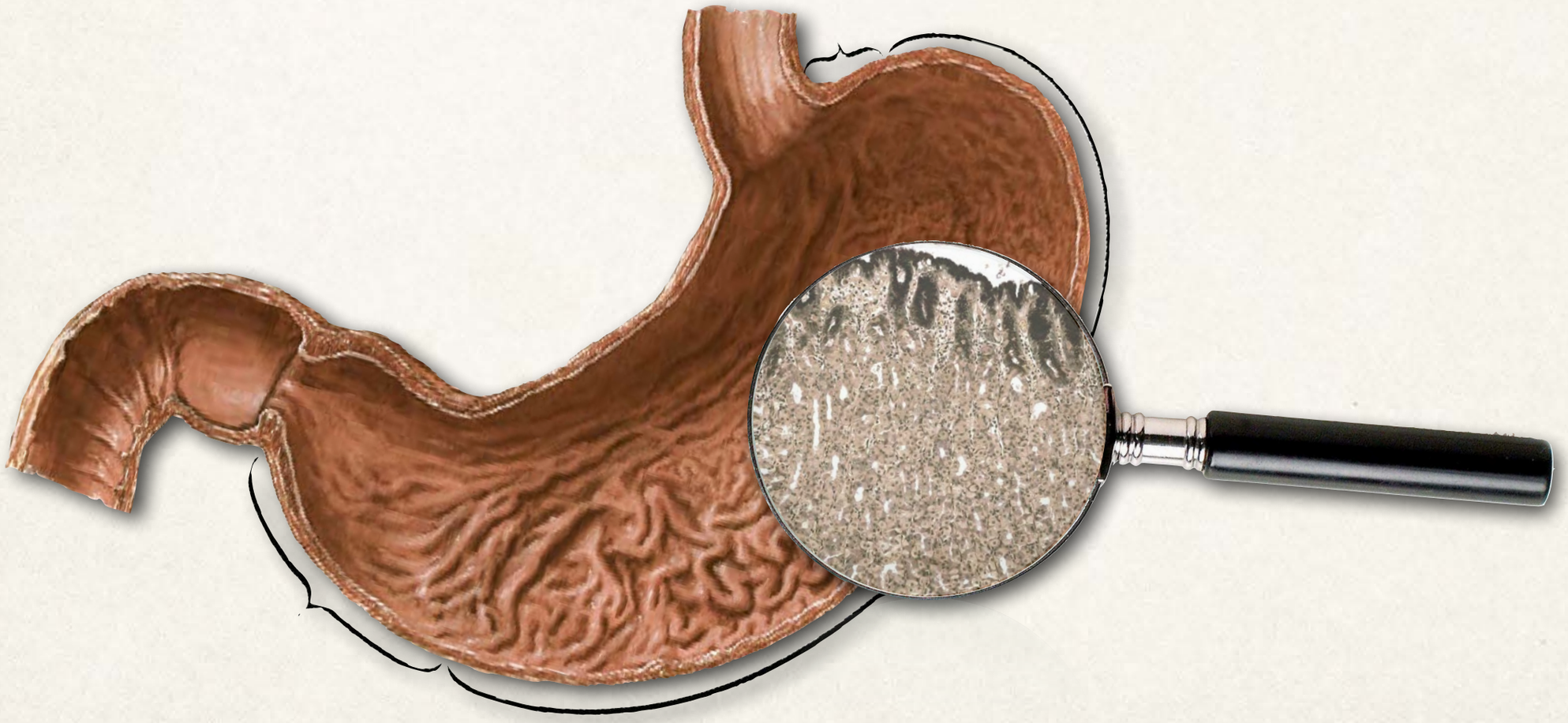

Af Mathias Gierløff Heitmann

11. Esophagus øvre

Hæmatoxylin-Eosin

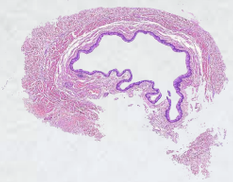

11A. Esophagus midt



Præp. 11A
Ekstra 1
BMI

12. Esophagus nederst

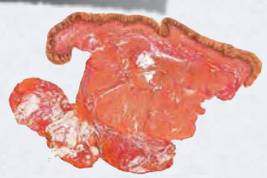

Præp. nr: 12
Kasse: 19
BMI

13. Fundus ventriculi

HE
PAS
Aurantia

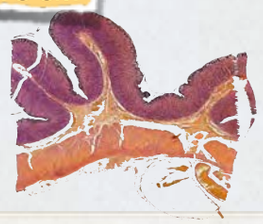

Præp. 13
Kasse 36
BMI

14. Pars pylorica

PAS

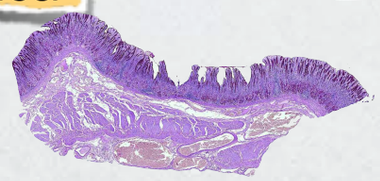

14A. Gastrin immunreaktion

Imunno-histokemisk

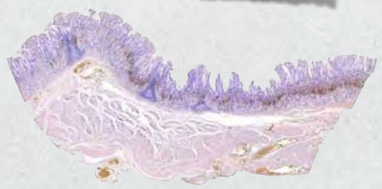

15. Pars pylorica og Duodenum

HE
PAS
Aurantia



Præp. 15
Kasse 48
BMI

16. Duodenum

Hæmatoxylin-Eosin
PAS

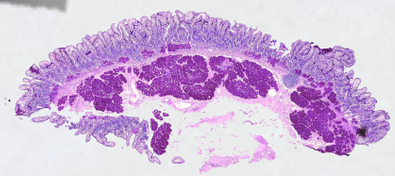

Præp. 16
Kasse 48
BMI

17. Jejunum

Hæmatoxylin-Eosin



Præp. 17
Kasse 48
BMI

18. Jejenum

HE
PAS
Aurantia



Præp. 18
Kasse 48
BMI

19. Appendix vermiformis ("Blindtarm")

Hæmatoxylin-Eosin

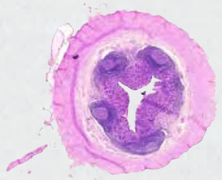

Præp. 19
Kasse 48
BMI

20. Colon

Hæmatoxylin-Eosin

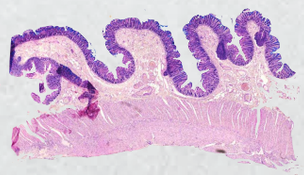

Præp. 20
Kasse 29
BMI

11. Øvre oesophagus

Mikroskopisk

Hæmatoxylin-Eosin

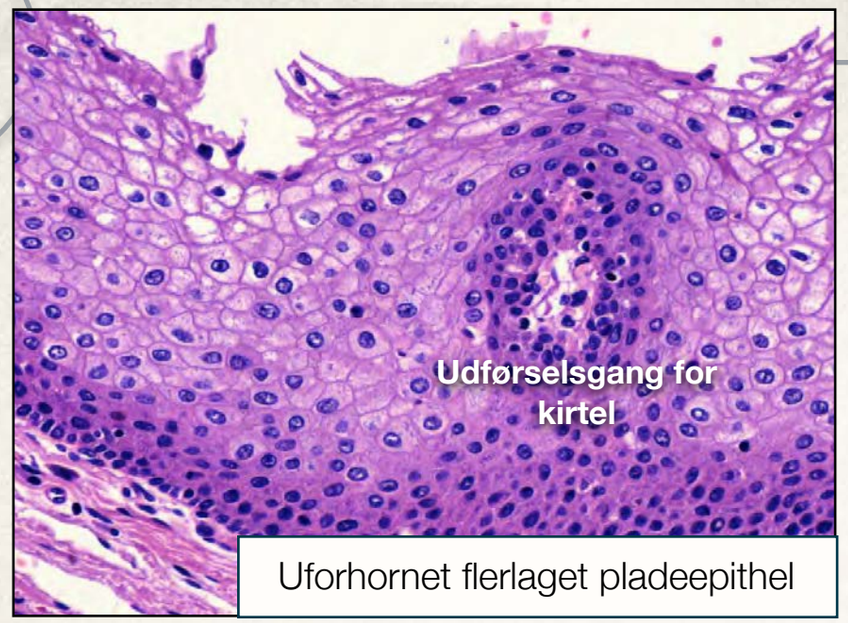

Uforhornet flerlaget pladeepithel

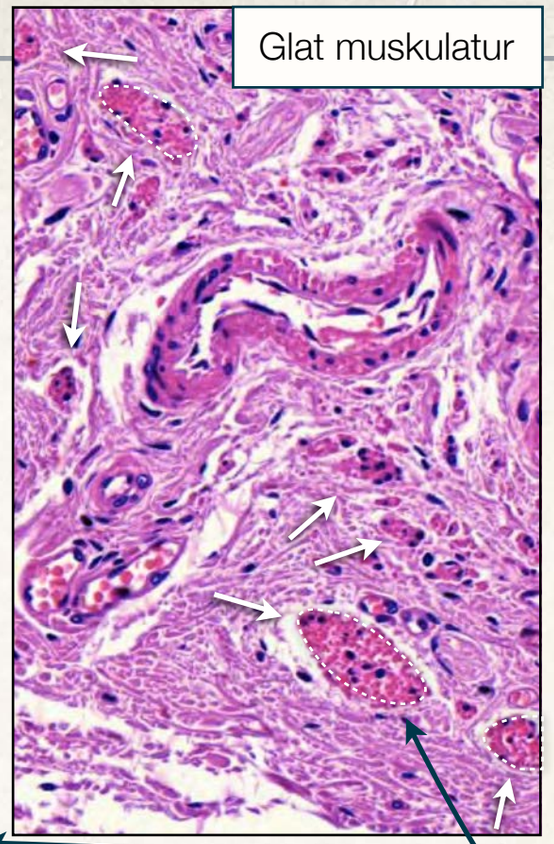

Glat muskulatur

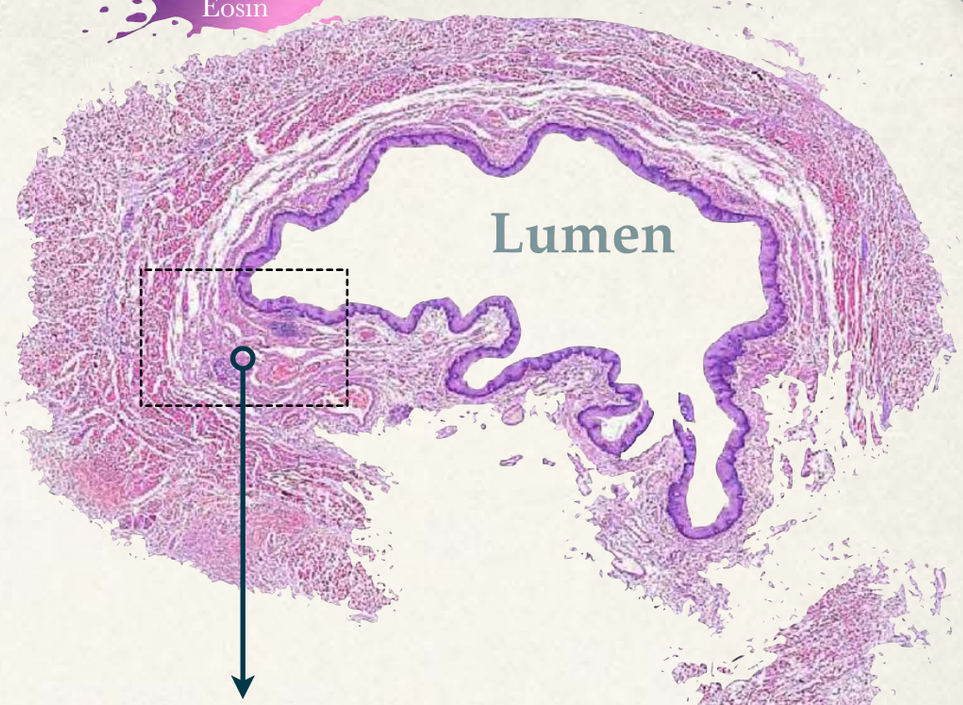

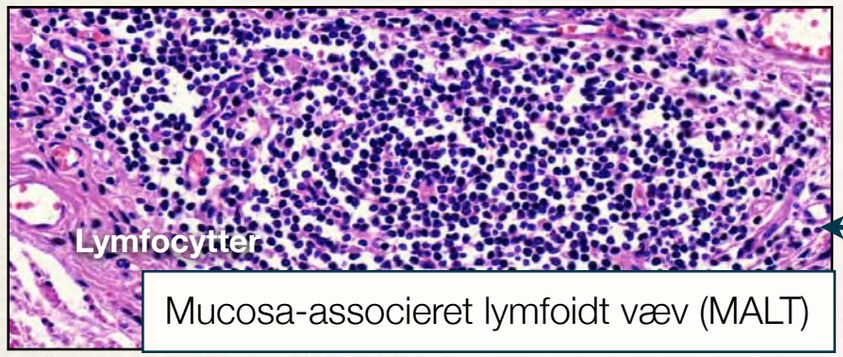

Mucosa-associeret lymfoidt væv (MALT)

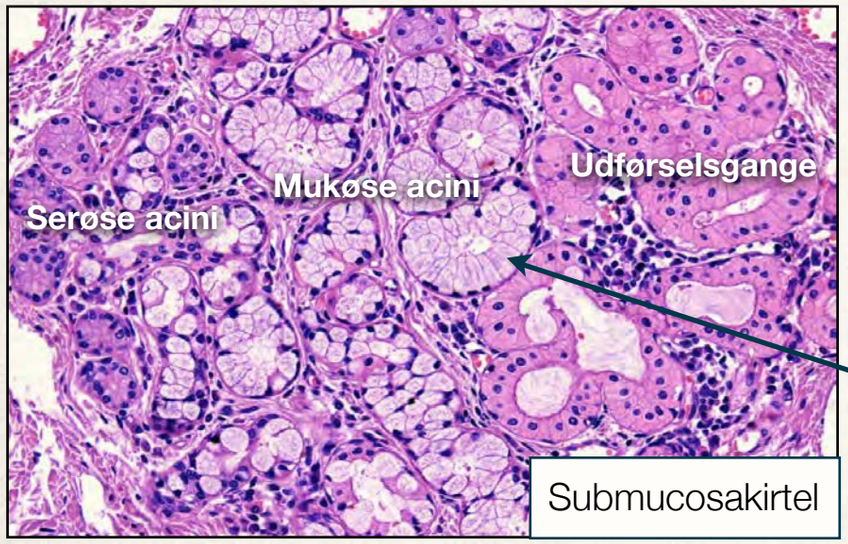

Submucosakirtel



Tværstribet muskulatur

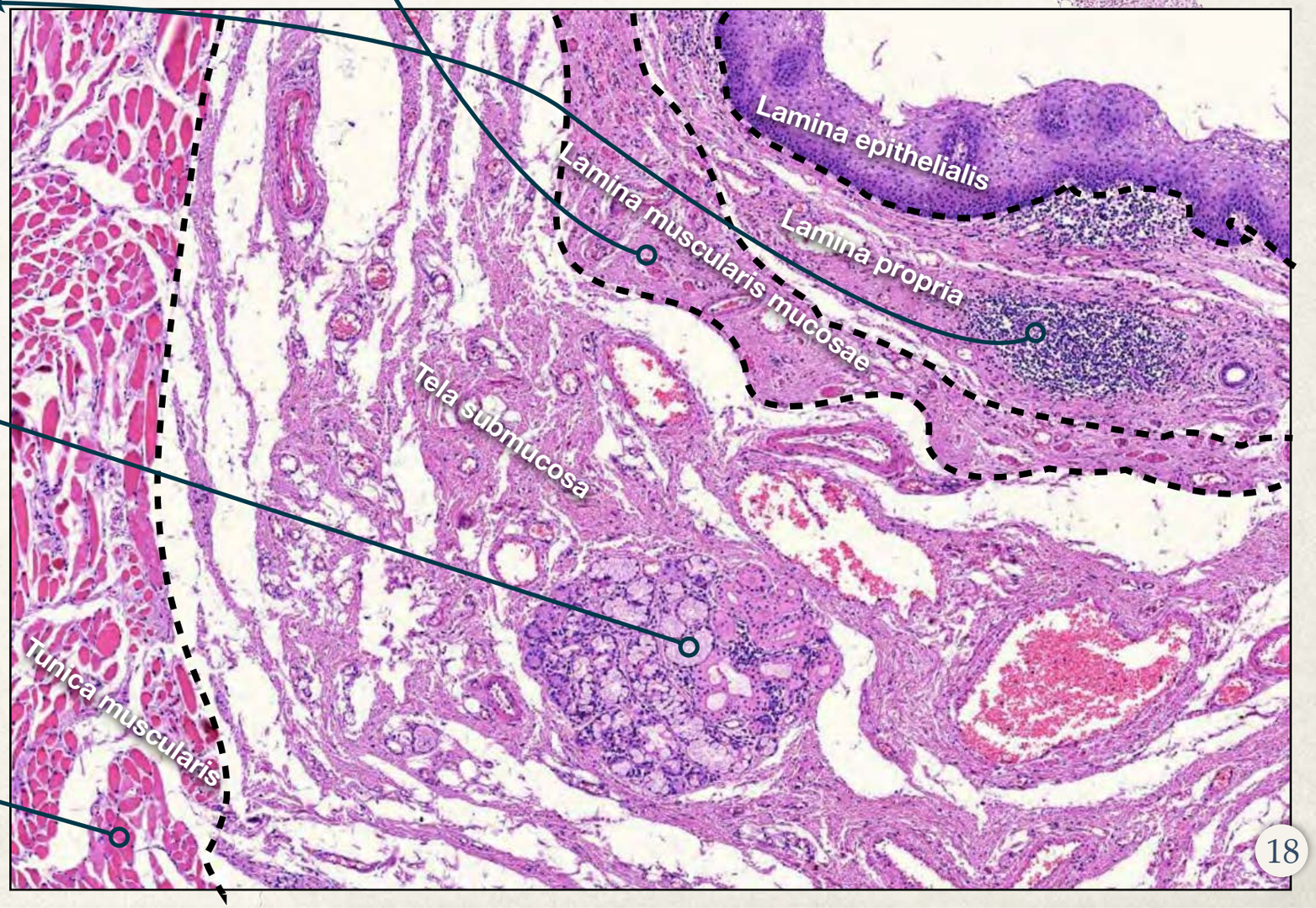

11A. Esophagus midt

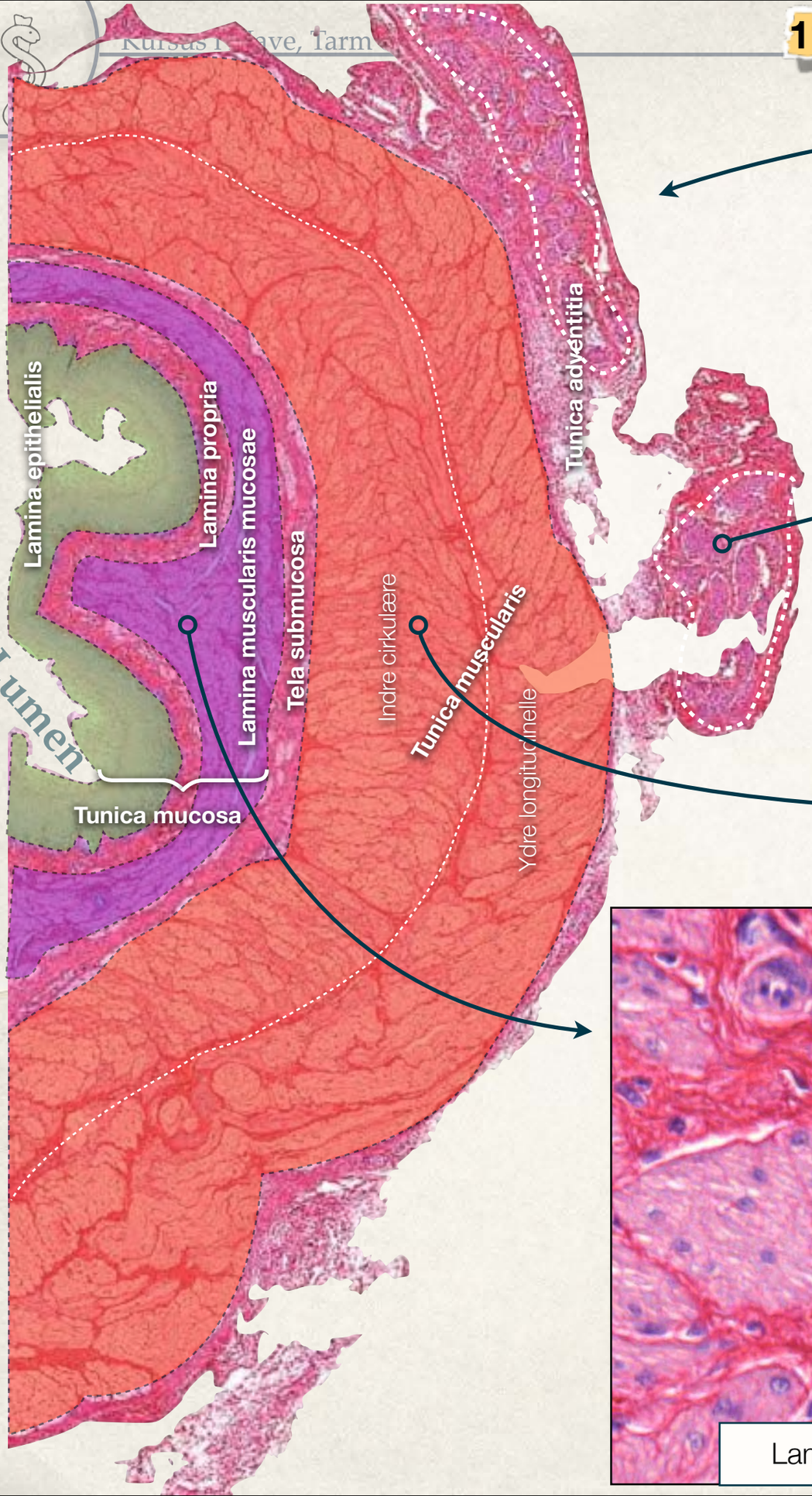

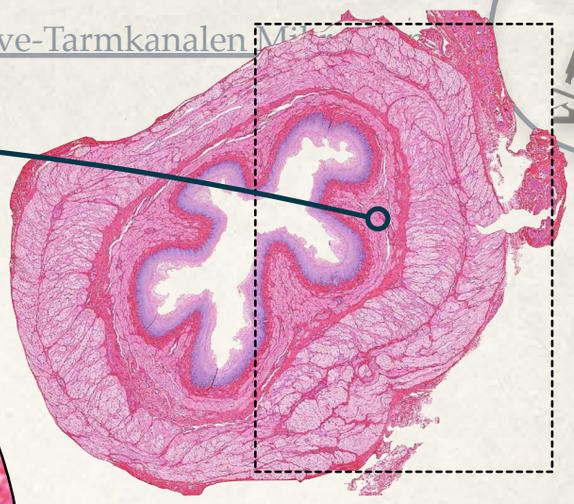

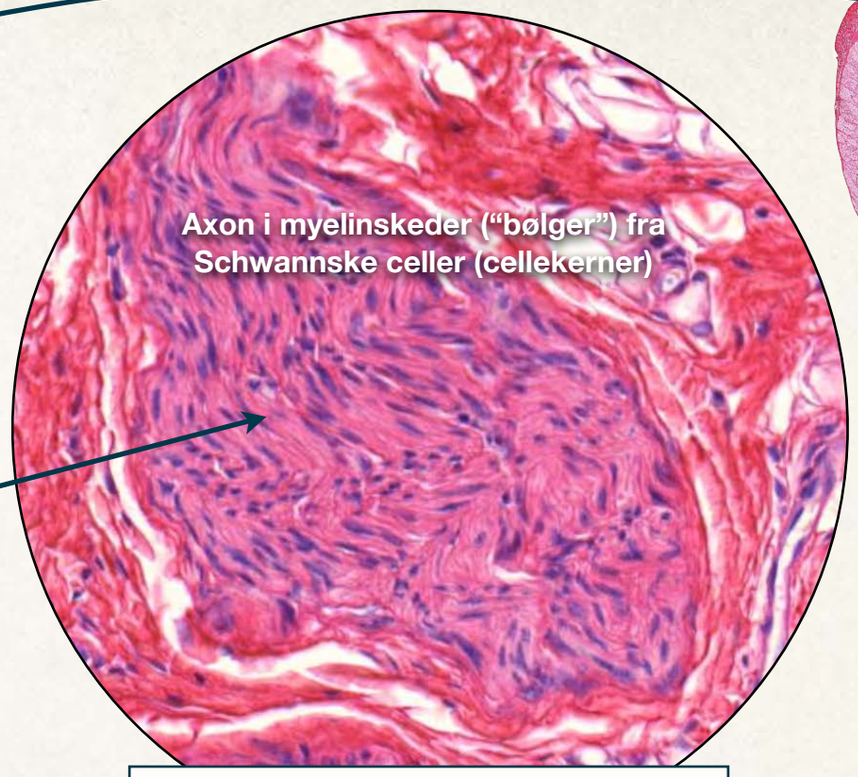

Plexus oesophageus (n. vagus)

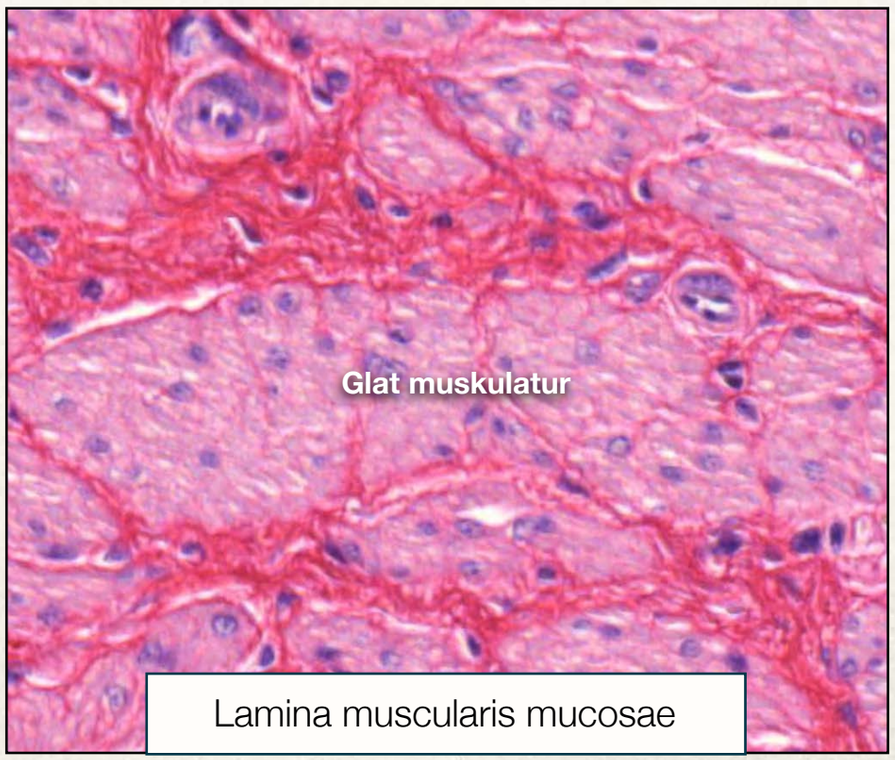

Lamina muscularis mucosae



Tunica muscularis, stratum circulare

12. Esophagus nederst

= Præparatets afskårne kant

Lumen

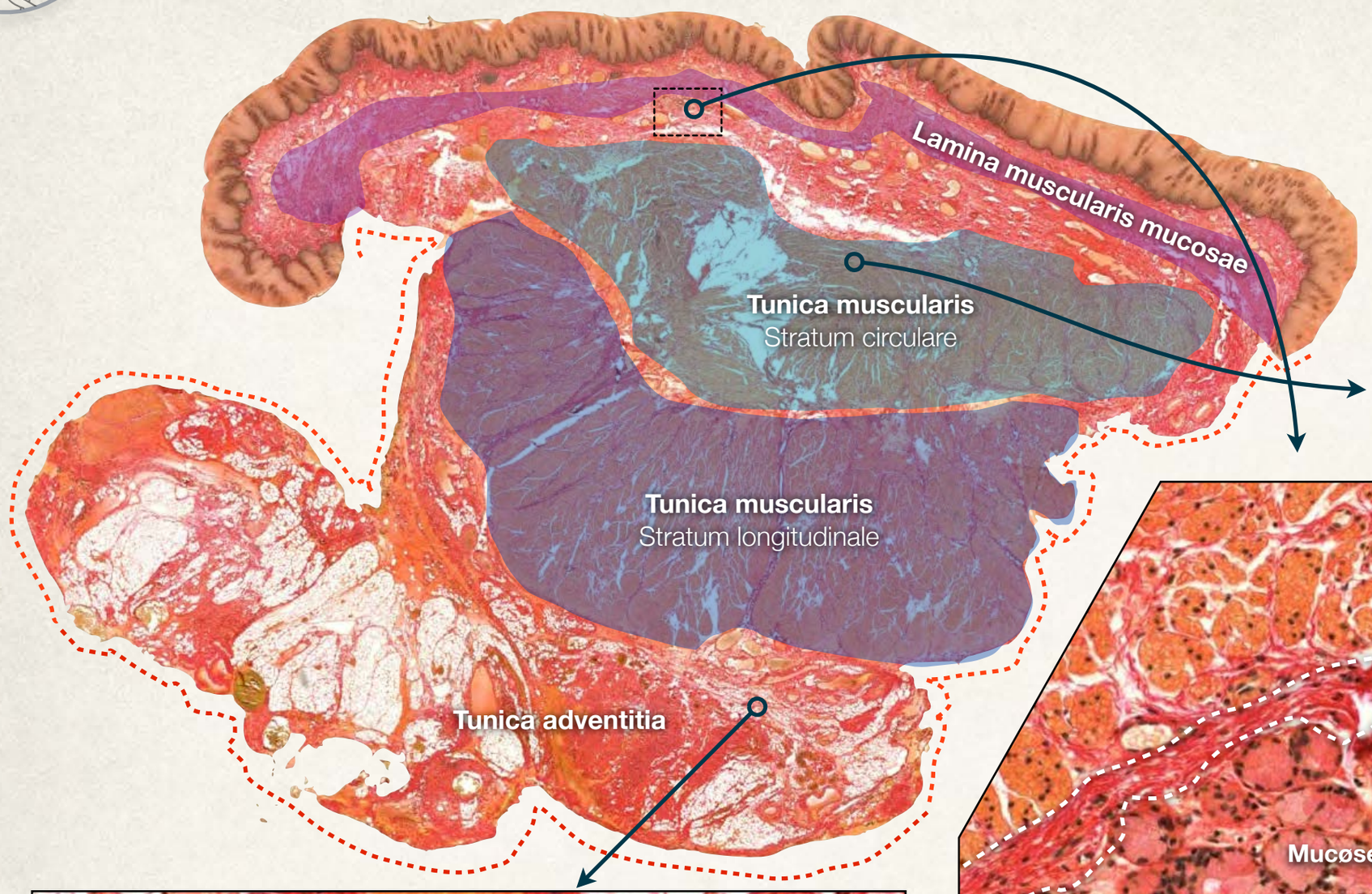

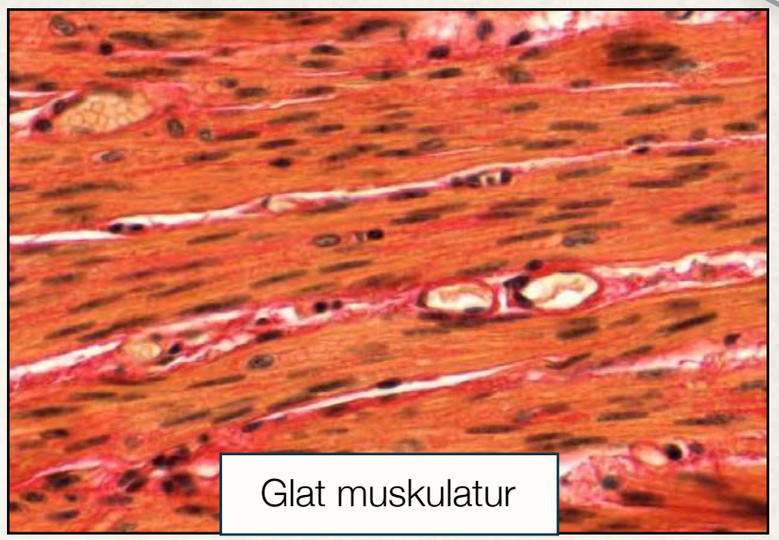

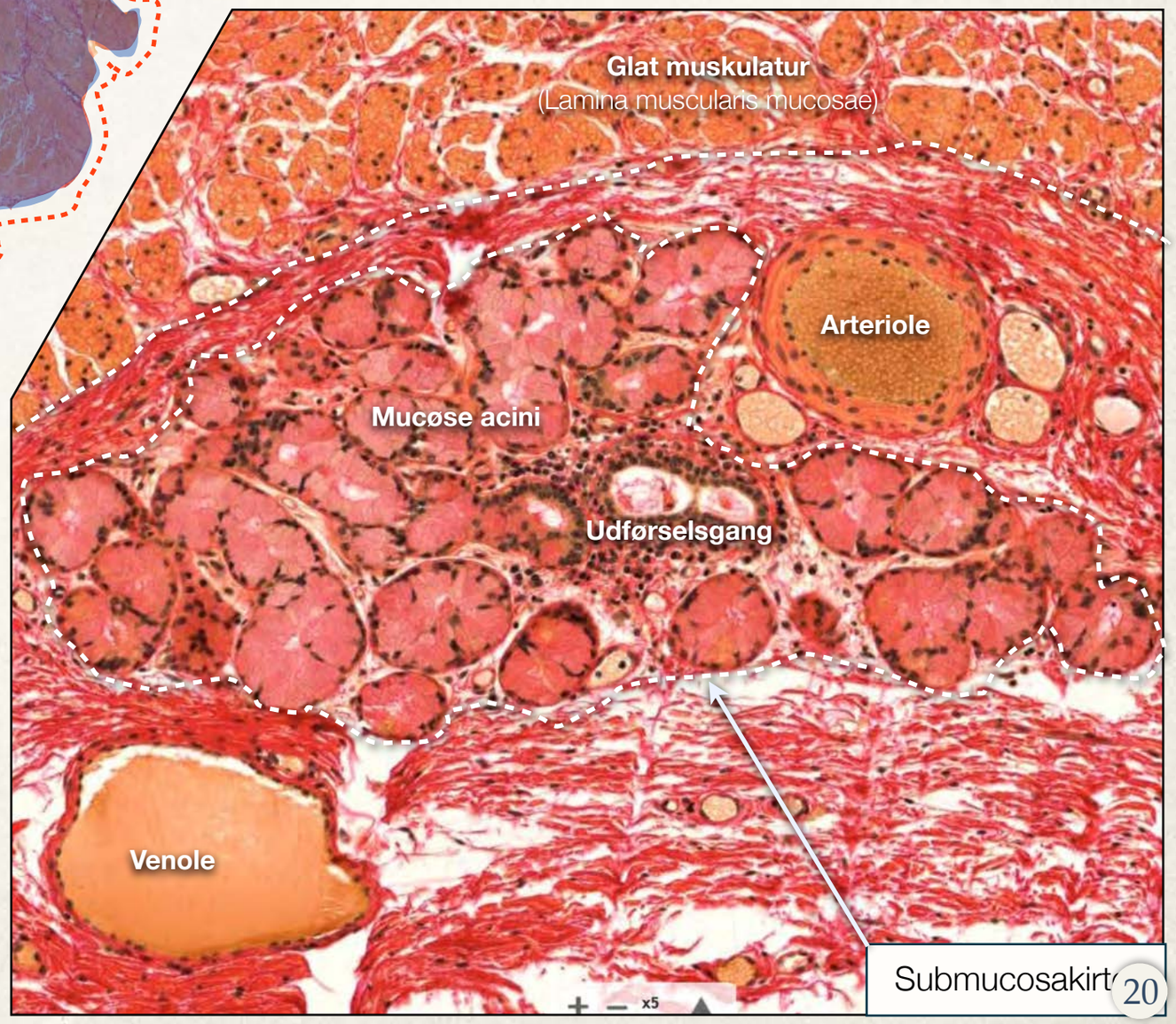

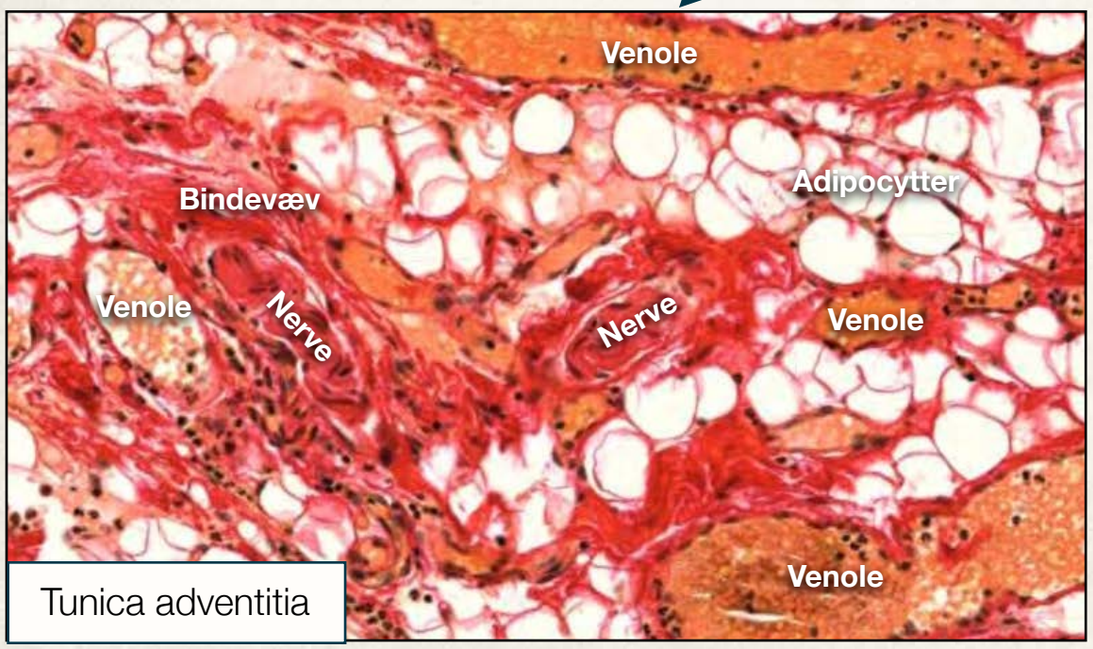

HE PAS Aurantia

13. Fundus ventriculi

Overblik

= Præparatets afskårne kant

Plica gastrica (rugae)

Lumen

Tunica mucosa

Tela submucosa

Tunica muscularis

Stratum obliquae

Stratum circulare

Stratum longitudinale

Tunica serosa

Cavitas peritonealis

Lumen

Lamina propria

Lamina epithelialis

Tunica mucosa

Lamina muscularis mucosae

Tela submucosa

HE PAS Aurantia

13. Fundus ventriculi

Corpus-fundus-kirtlen

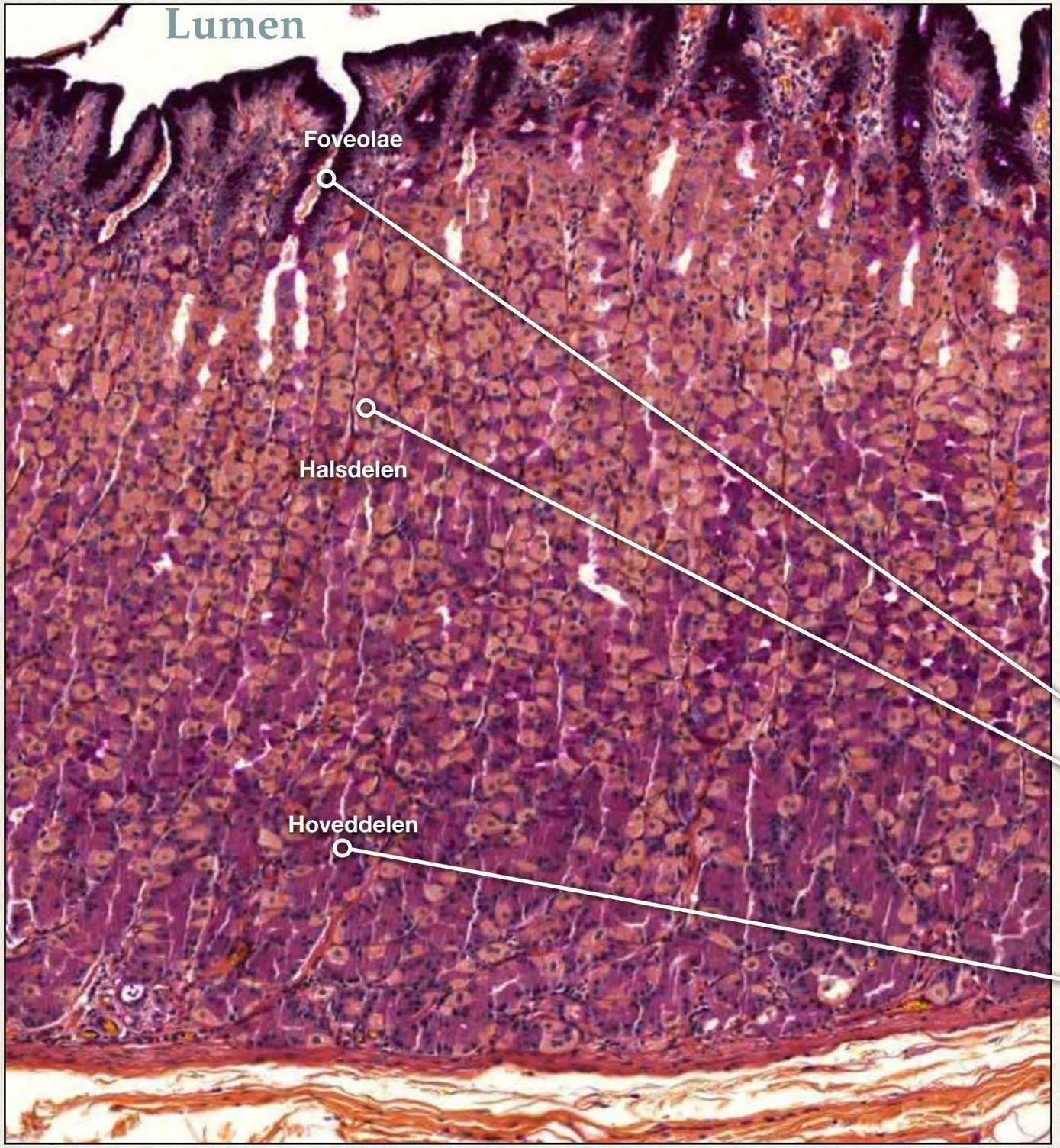

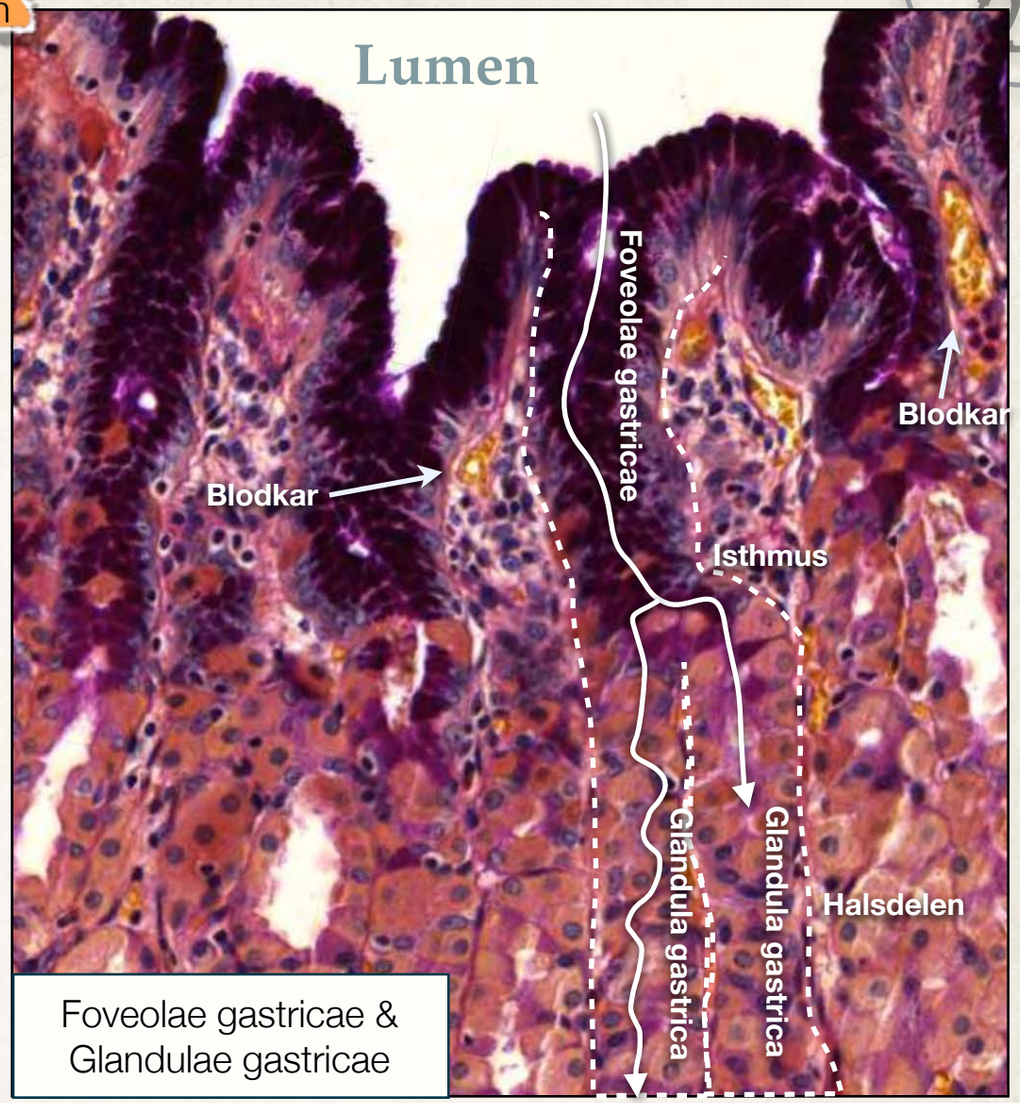

Foveolae gastricae & Glandulae gastricae

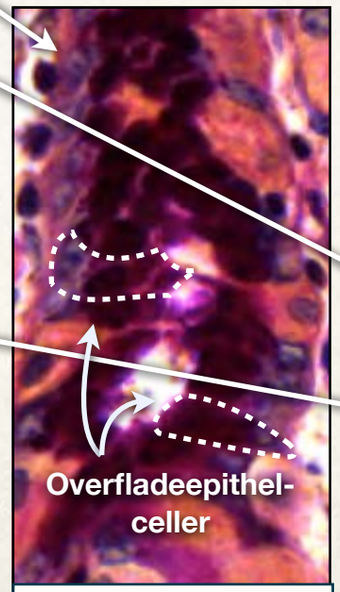

Foveolae gastricae

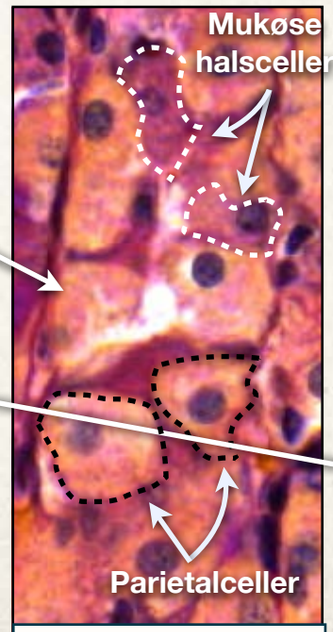

Halsdelen

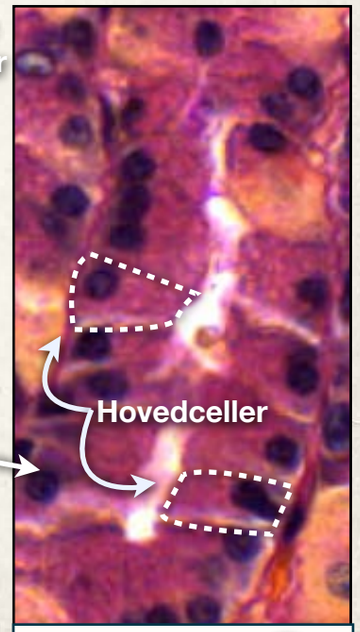

Hoveddele

14. Pars pylorica

PAS

Lumen

Tunica mucosa

Tela submucosa

Tunica muscularis

Tunica serosa

Lumen

Lamina epithelialis

Lamina propria

Tunica mucosa

Område med mange enteroendokrine celler

Pyloruskirtlen

Lymfocytter (MALT) beliggende i Lamina propria

Lamina muscularis mucosae

Dybe foveola

Overfladeepithel-celler

Lamina epithelialis

Basalmembran

Lamina propria

Basalmembran

Pars pylorus-kirtel

Mukøse kirtelceller

Imunno-histokemisk

14A. Gastrin immunreaktion

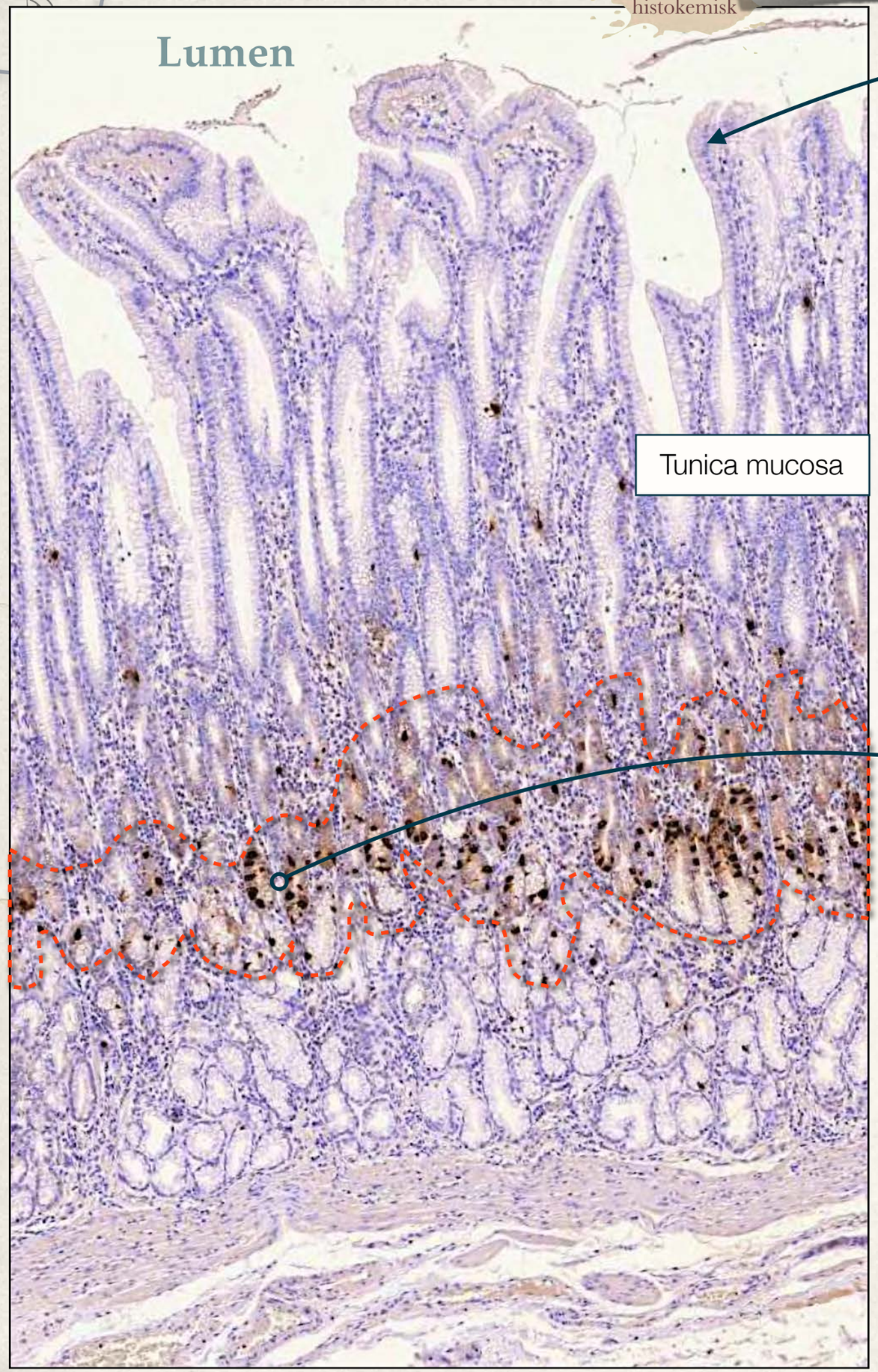

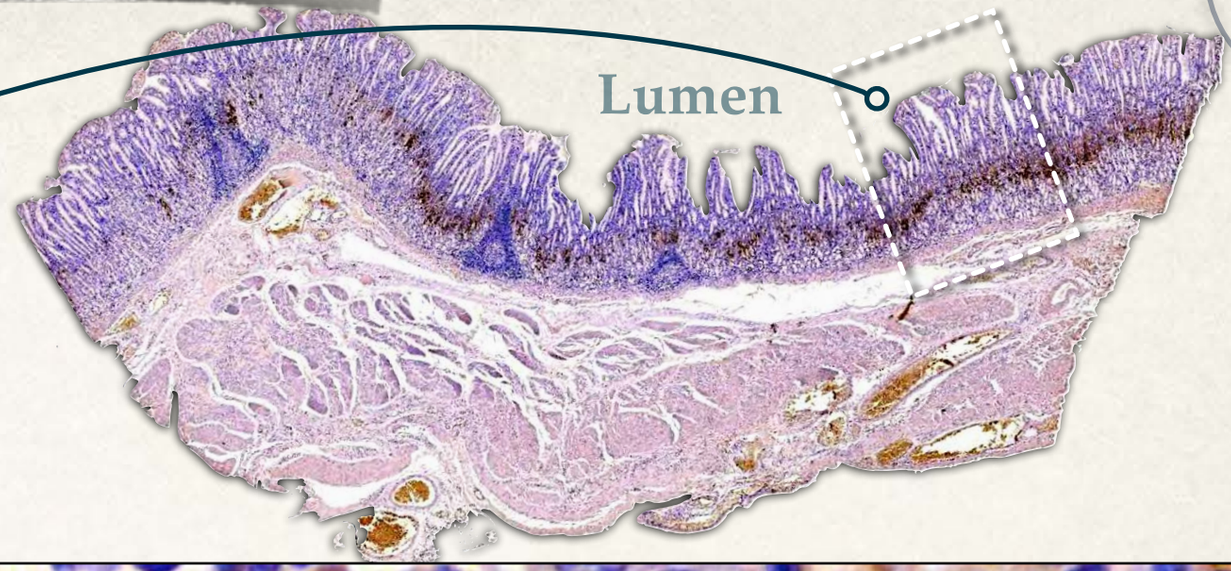

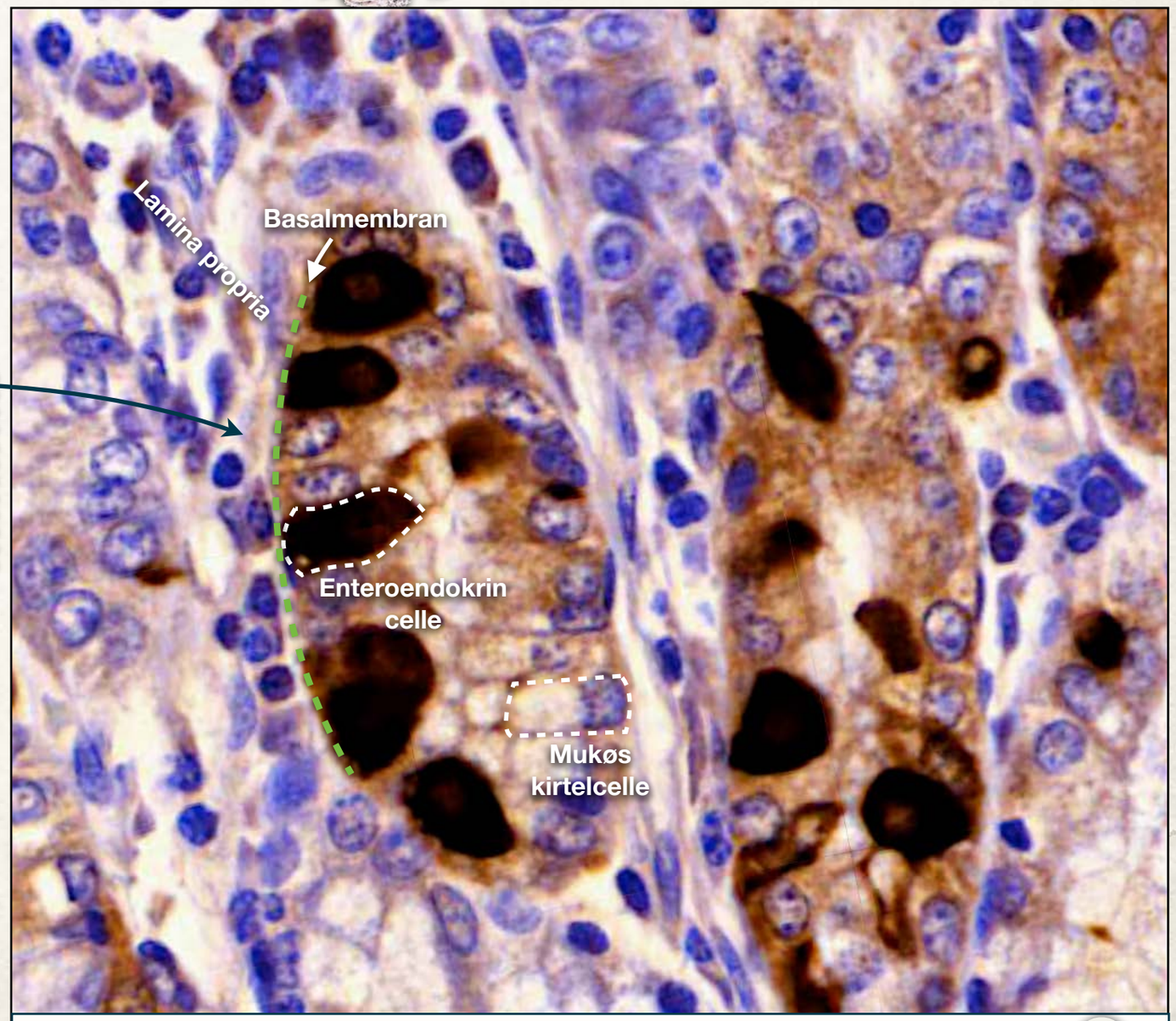

Enteroendokrine celler: G-celler (Gastrin) samt D-celler (Somatostatin)

HE PAS Aurantia

15. Pars pylorica og Duodenum

Lumen

M. sphincter pylori

Canalis pyloricus

Bulbus (Ampulla) duodeni

Lamina muscularis mucosae

Brunnerske kirtler

Duodenum

Lumen

Foveola gastrica

Glandula gastrica (pyloruskirtler)

Pyloruskirtler

Lumen

Artefakt

Artefakt

Artefakt

Artefakt

Artefakt

Villus intestinalis

Mukøse acini

Brunnerske kirtler (Glandulae duodenales)

16. Duodenum

Hæmatoxylin-Eosin PAS

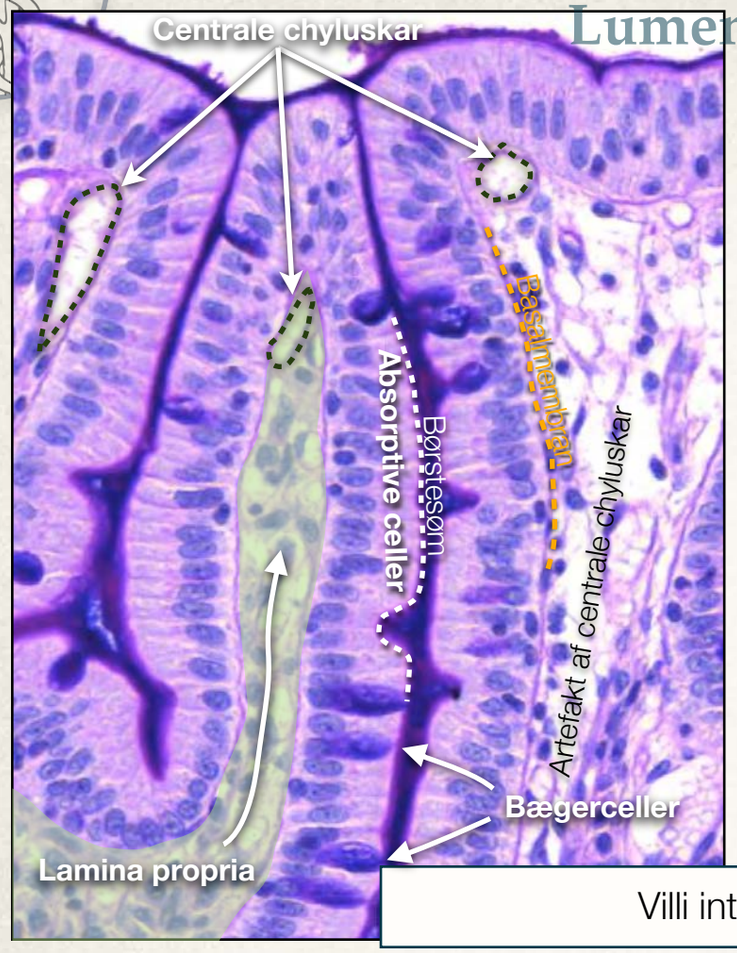

Villi intestinales



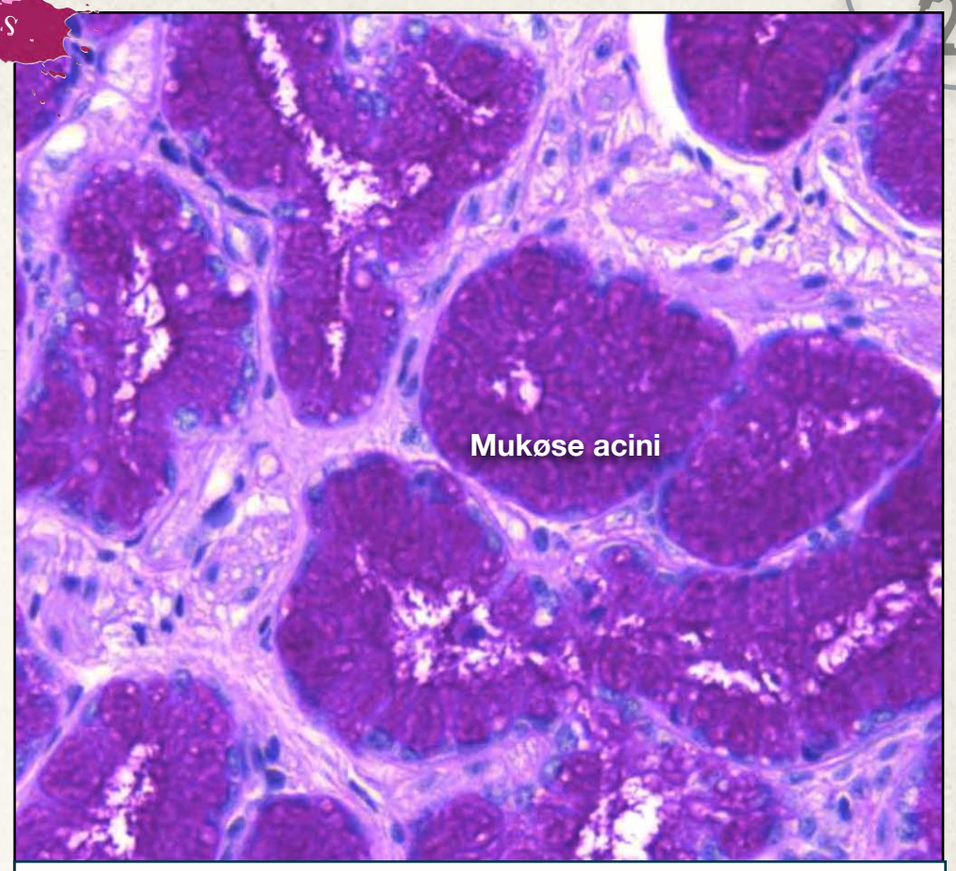

Brunnerske kirtler (glandulae duodenales)

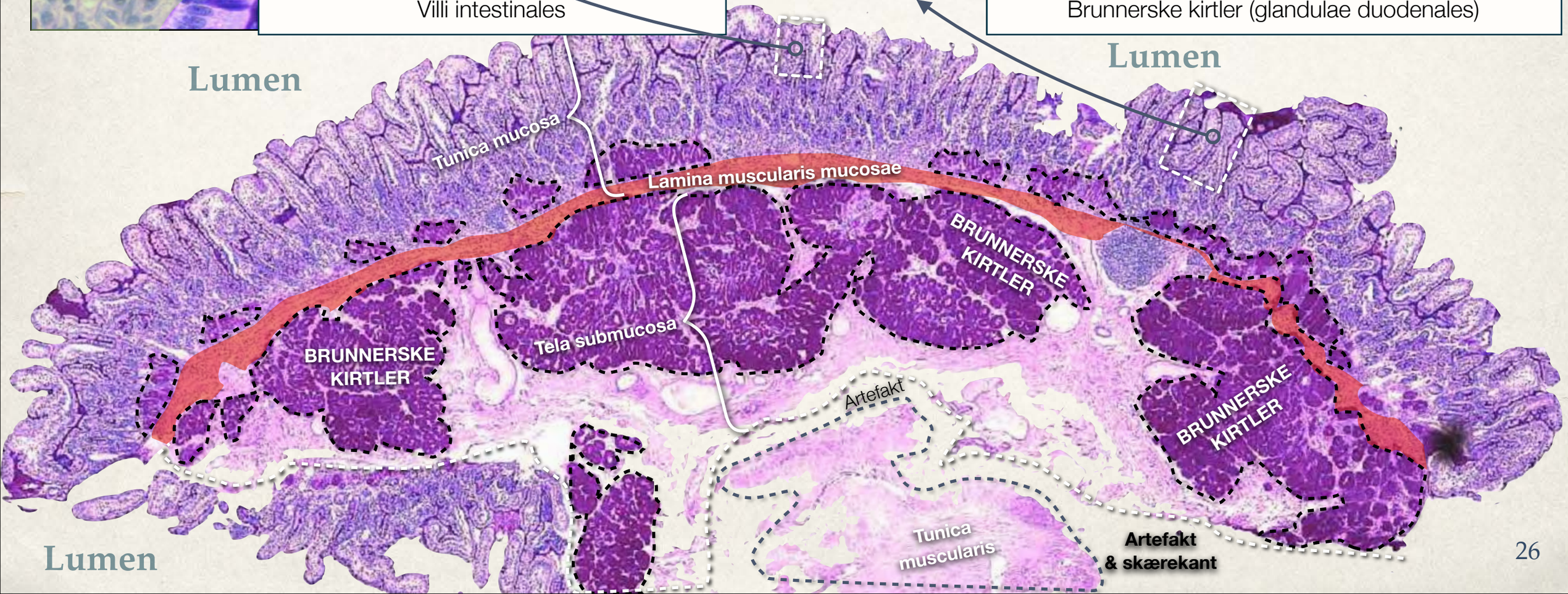

17. Jejunum

Hæmatoxylin Eosin

= Præparatets afskårne kant

Artefakt

Lumen

Villi intestinales

Plica circularis

Tela submucosa

Plica circularis

Stratum circulare

Stratum longitudinale

Tunica muscularis

Granula (Panethceller)

Lieberkühsk krypt

"Lærebogsbillede"

Lamina propria

Villus intestinalis

Villus intestinalis

Panethceller

Lieberkühnsk krypt

18. Jejenum

HE
PAS
Auranti

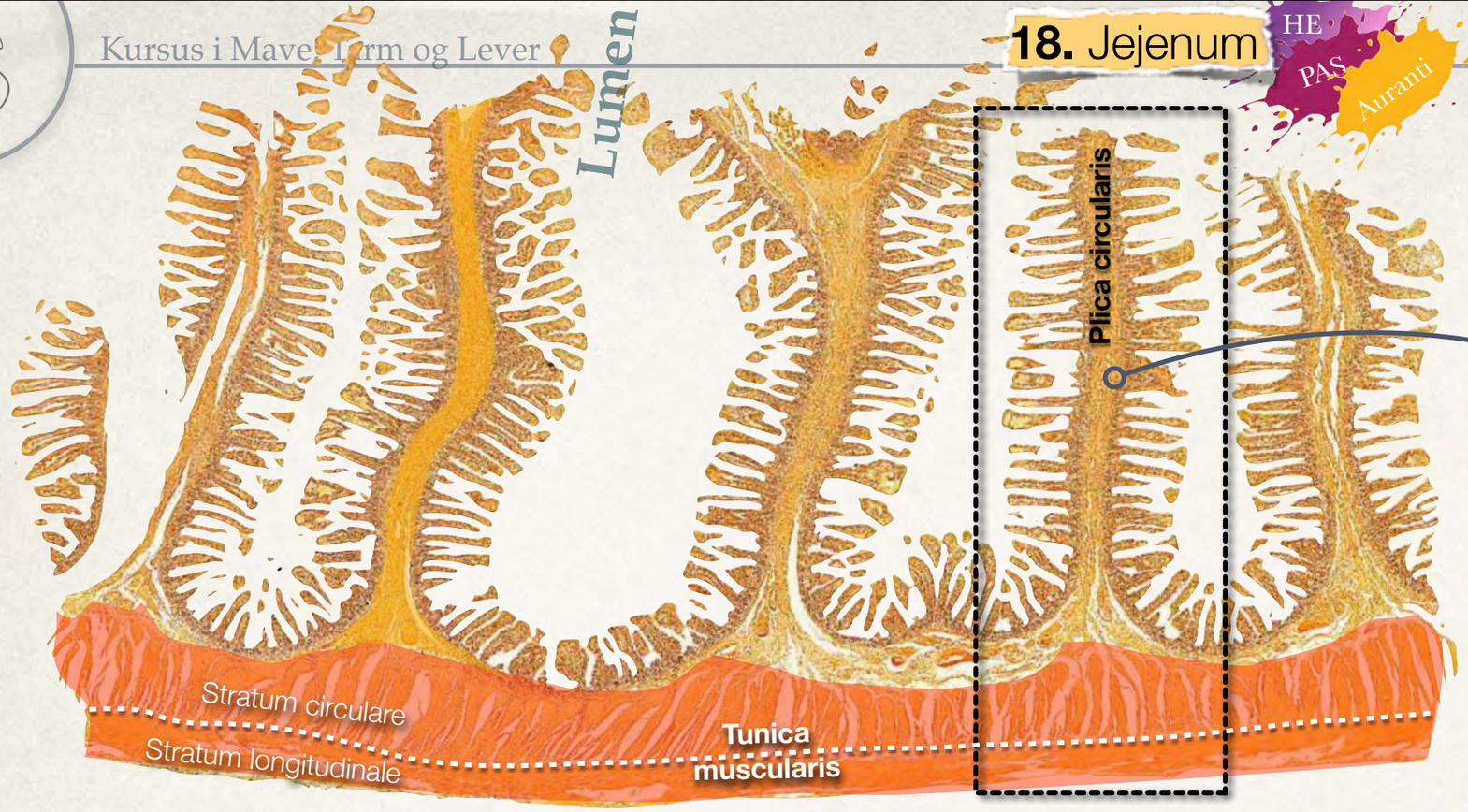

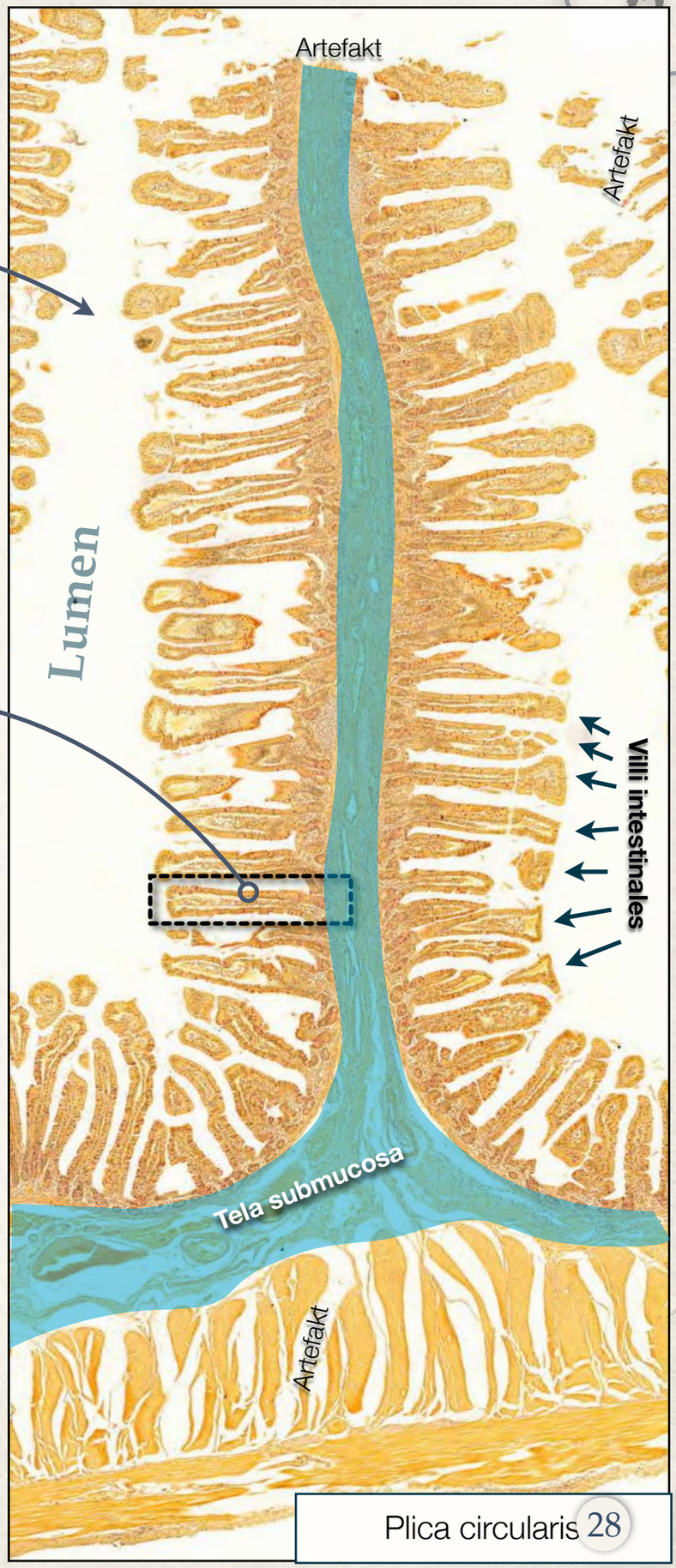

Plica circularis

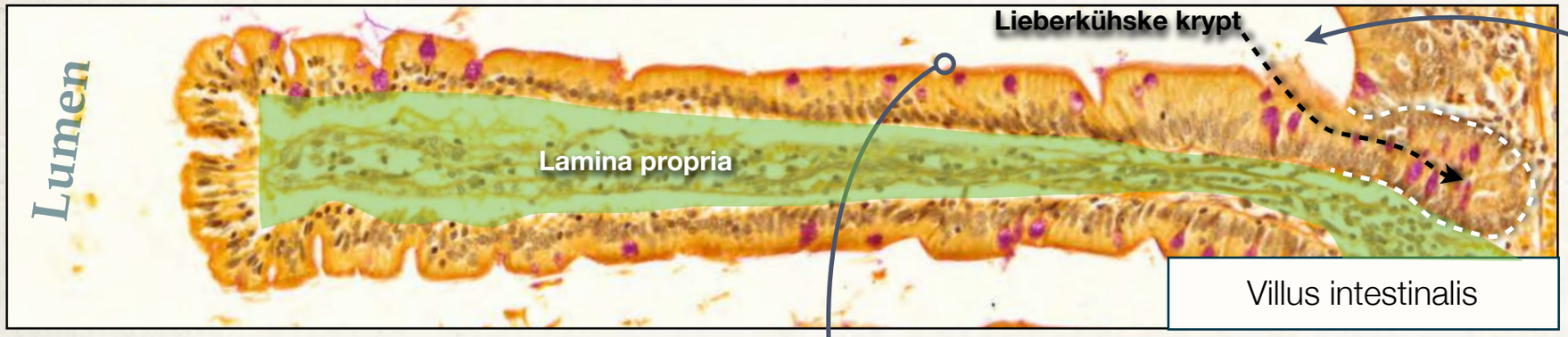

Villus intestinalis

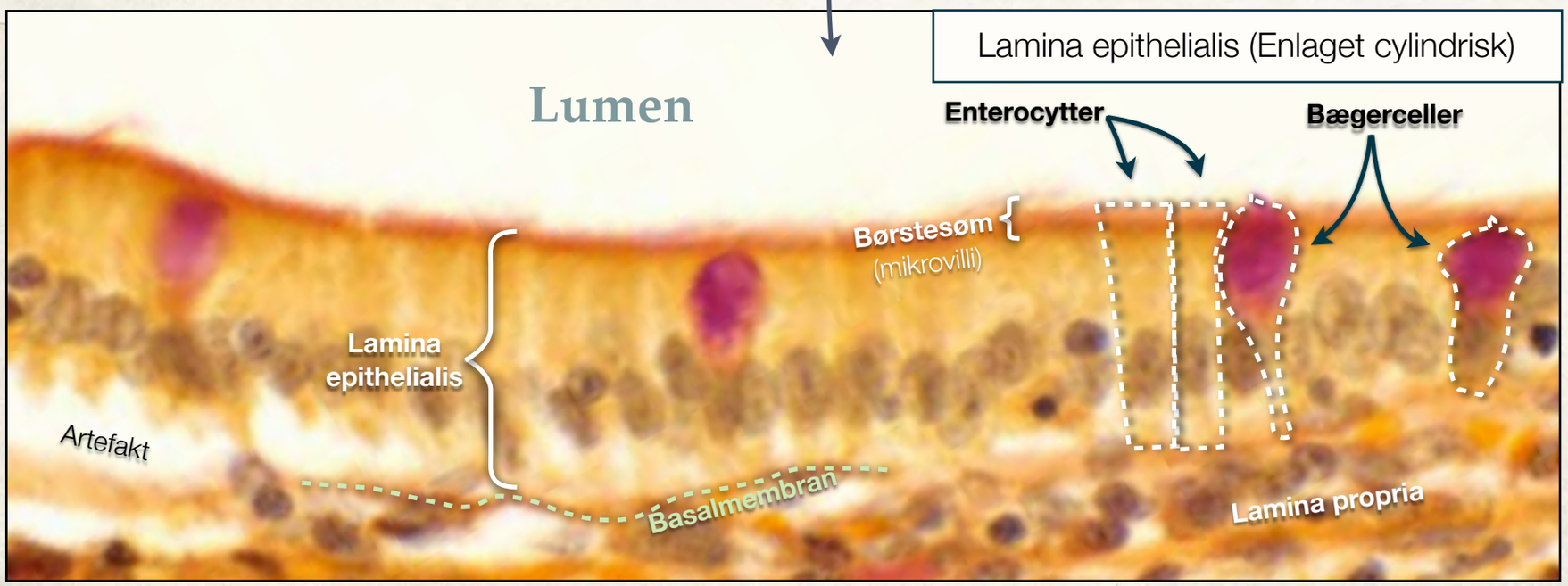

Lamina epithelialis (Enlaget cylindrisk)

19. Appendix vermiformis ("Blindtarm")

Hæmatoxylin
Eosin

Børstesøm
Absorptive celler
Lumen
Lamina epithelialis
Lamina propria
Bægerceller
Lieberkühnsk krypt
Lieberkühnsk krypt

Tunica mucosa

Talrige leukocytter (hvide blodlegemer)

Stratum longitudinale
Tunica muscularis
Stratum circulare
Tela submucosa
Lumen

Artefakt
Artefakt
Artefakt

Lymfoid follikel (leukocytter)

Stratum longitudinale
Stratum circulare

Tunica serosa (mesothel)/
Peritoneum viscerale

Cavitas peritonealis

20. Colon

Hæmatoxylin Eosin

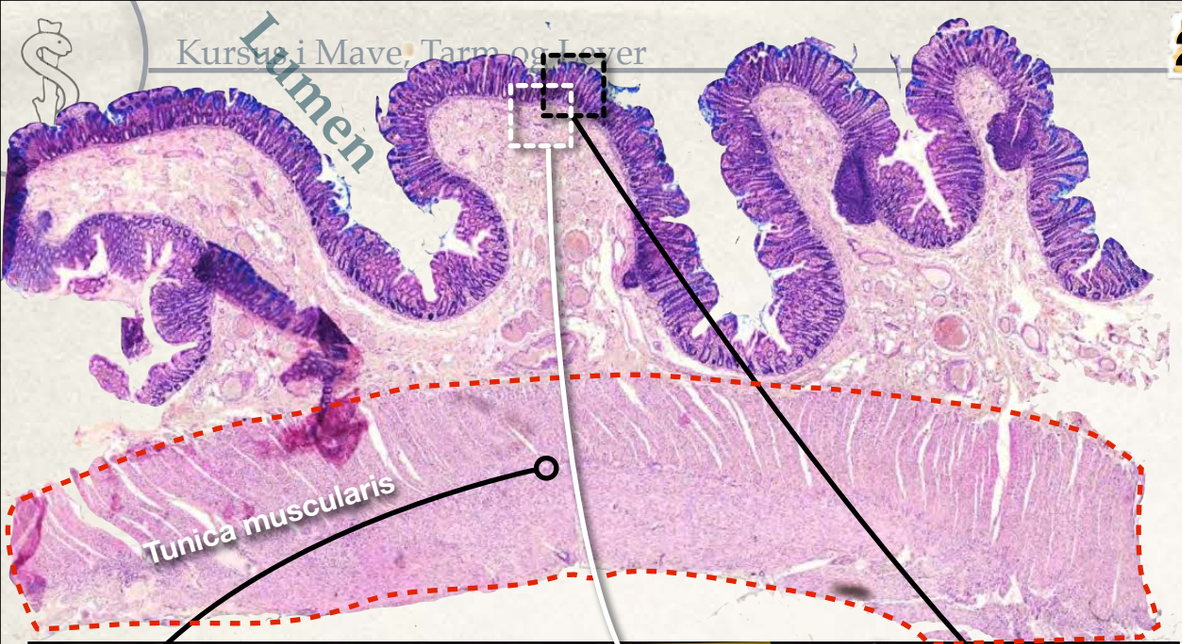

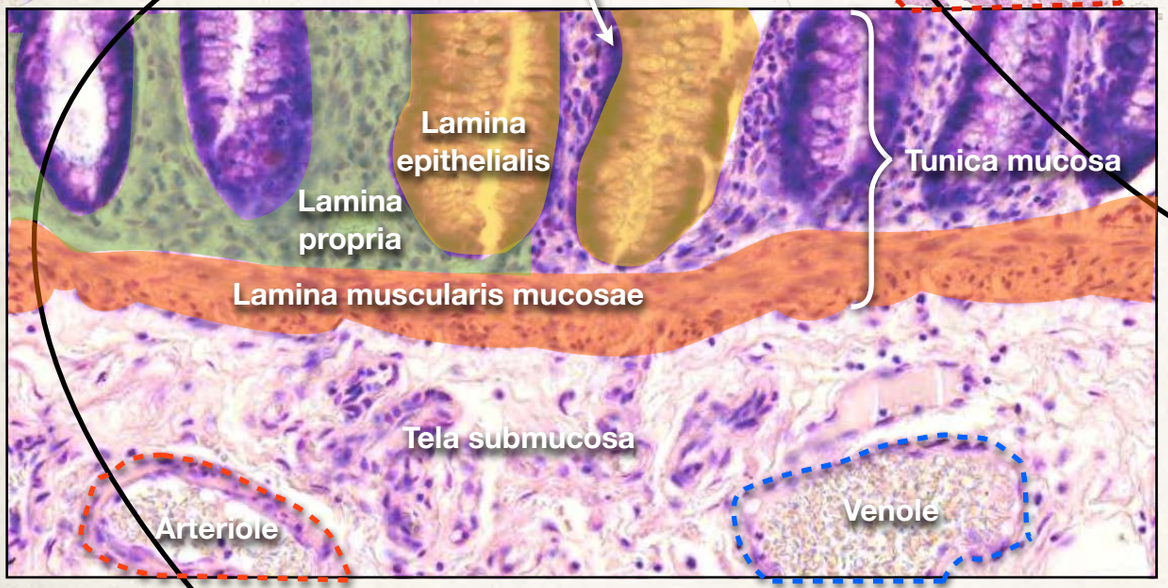

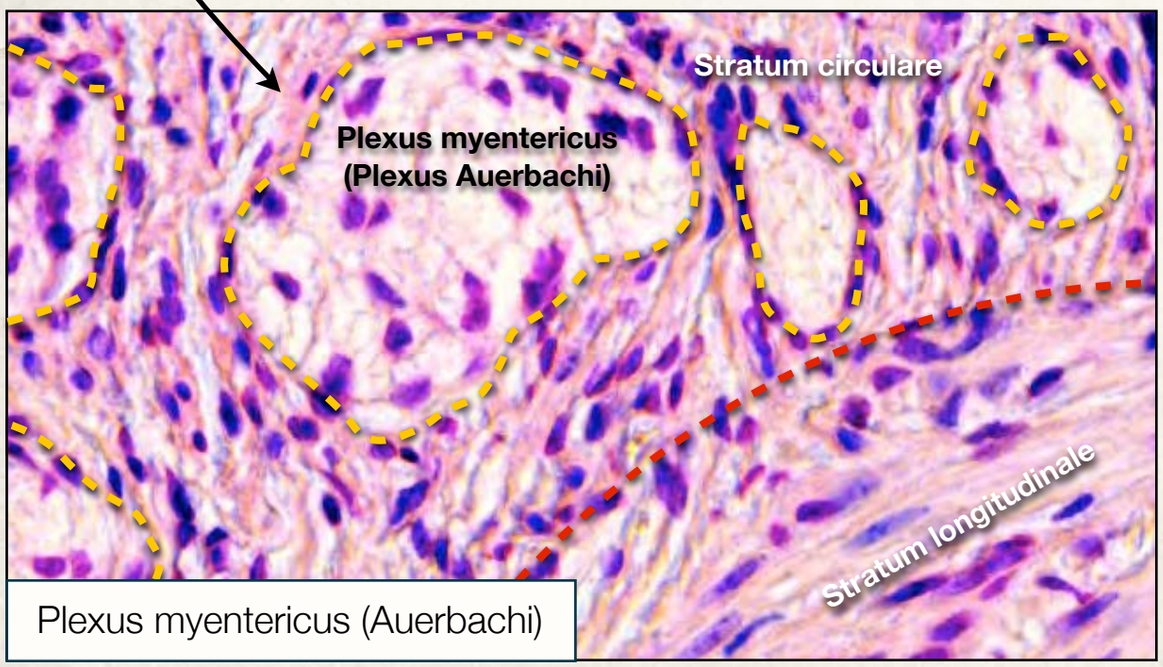

Plexus myentericus (Auerbachi)

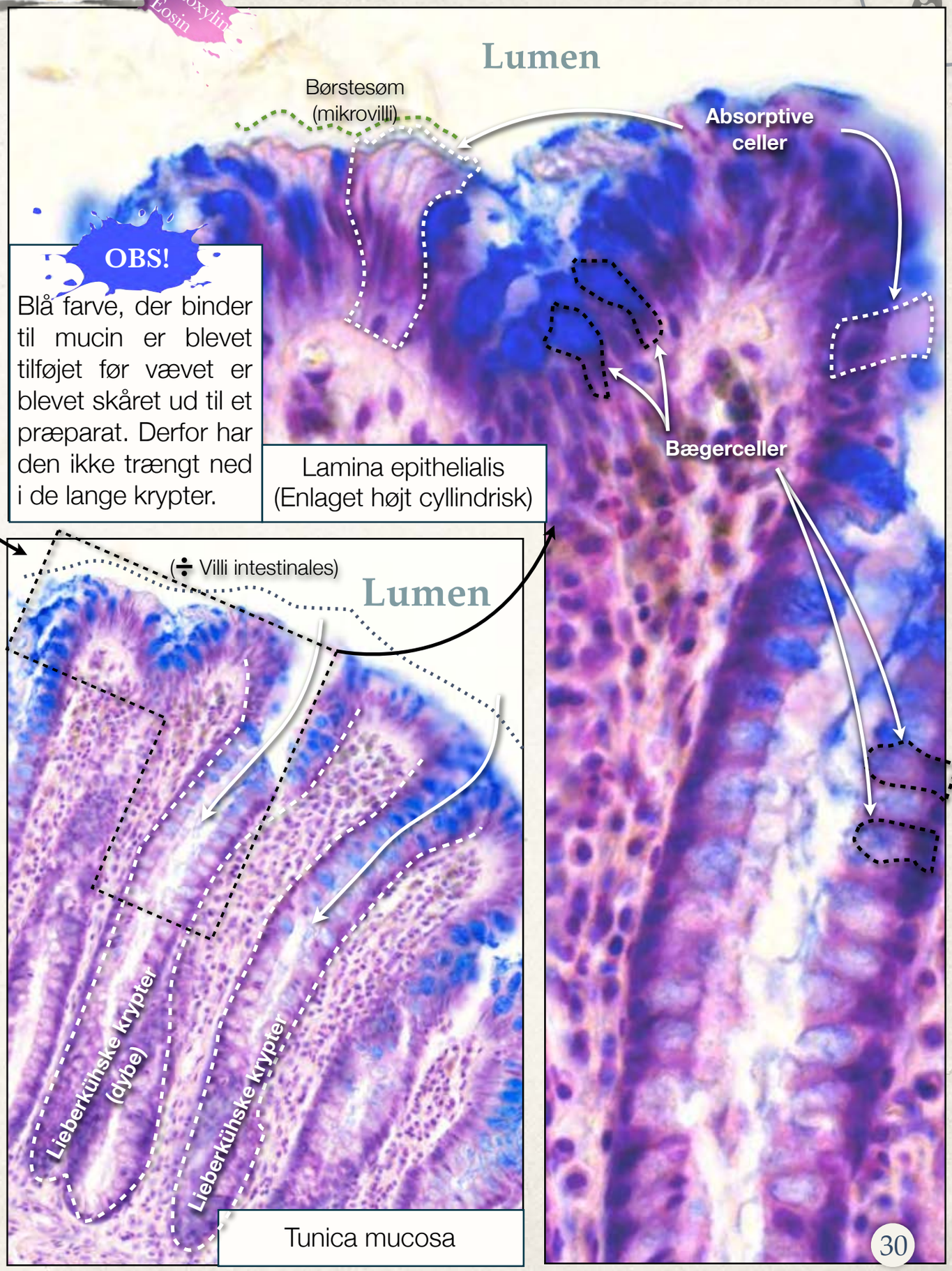

OBS!

Blå farve, der binder til mucin er blevet tilføjet før vævet er blevet skåret ud til et præparat. Derfor har den ikke trængt ned i de lange krypter.

Lamina epithelialis
(Enlaget højt cyllindrisk)

Tunica mucosa

MIKROSKOPISK SPOTGUIDE

Lever, Galdeveje & Spytkirtler



Af Anders Gullach

21. Lever

Rød
Kar-injektioner
Blå

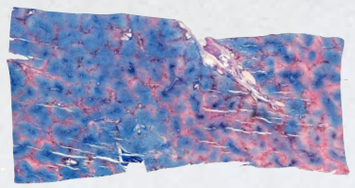

BMI
Præp. 21
Kasse 36

22. Lever med sinusioder

Siriusrød

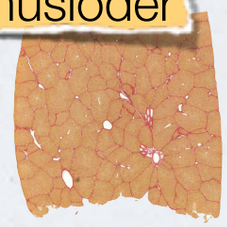

BMI
Præp. 22
Kasse 48

24. Glandula parotis

Siriusrød

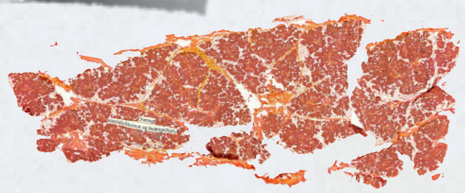

BMI
Præp. 24
Kasse 36

25. Glandula submandibularis

Hæmatoxylin-
Eosin

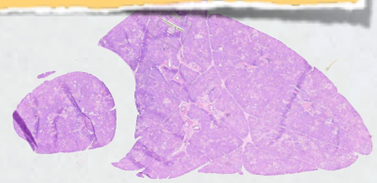

BMI
Præp. 25
Kasse 48

25A. Glandula submandibularis

PAS

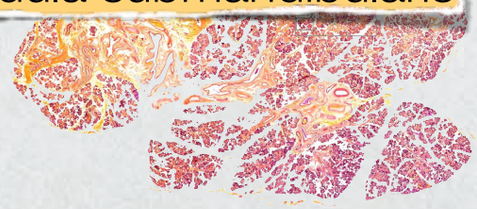

BMI
Præp. 25A
Ekstra 5

26. Glandula sublingualis

Hæmatoxylin-
Eosin

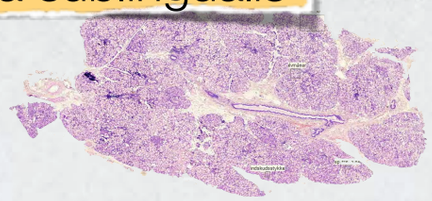

BMI
Præp. 26
Kasse 48

27. Pancreas

Hæmatoxylin-
Eosin

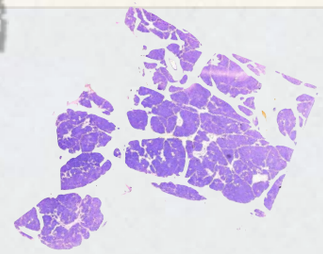

BMI
Præp. 27
Kasse 48

28. Insulin immunreaktion

Imunno-
histokemisk

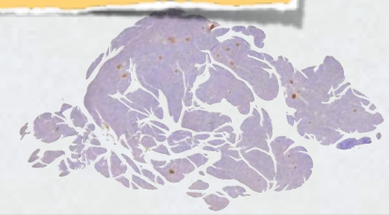

BMI
Præp. 28
Kasse85

29. Glucagon immunreaktion

Imunno-
histokemisk

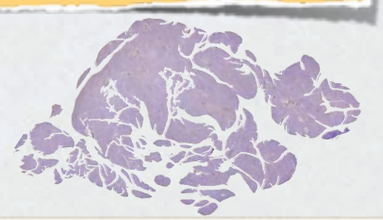

BMI
Præp. 29
Kasse 31

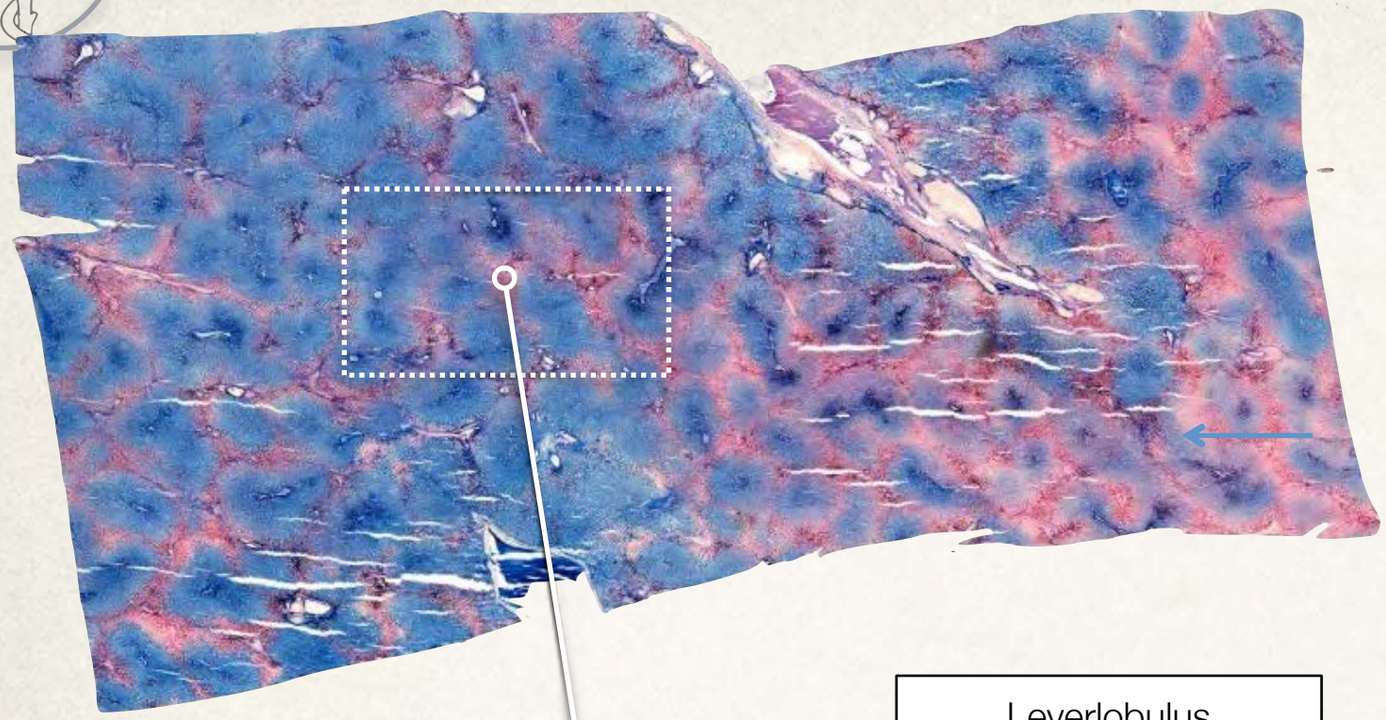

OBS!
Kar-injektioner

Der er injiceret Rødt farvestof i v. portae

og Blåt farvestof i vv. hepaticae

Leverlobulus

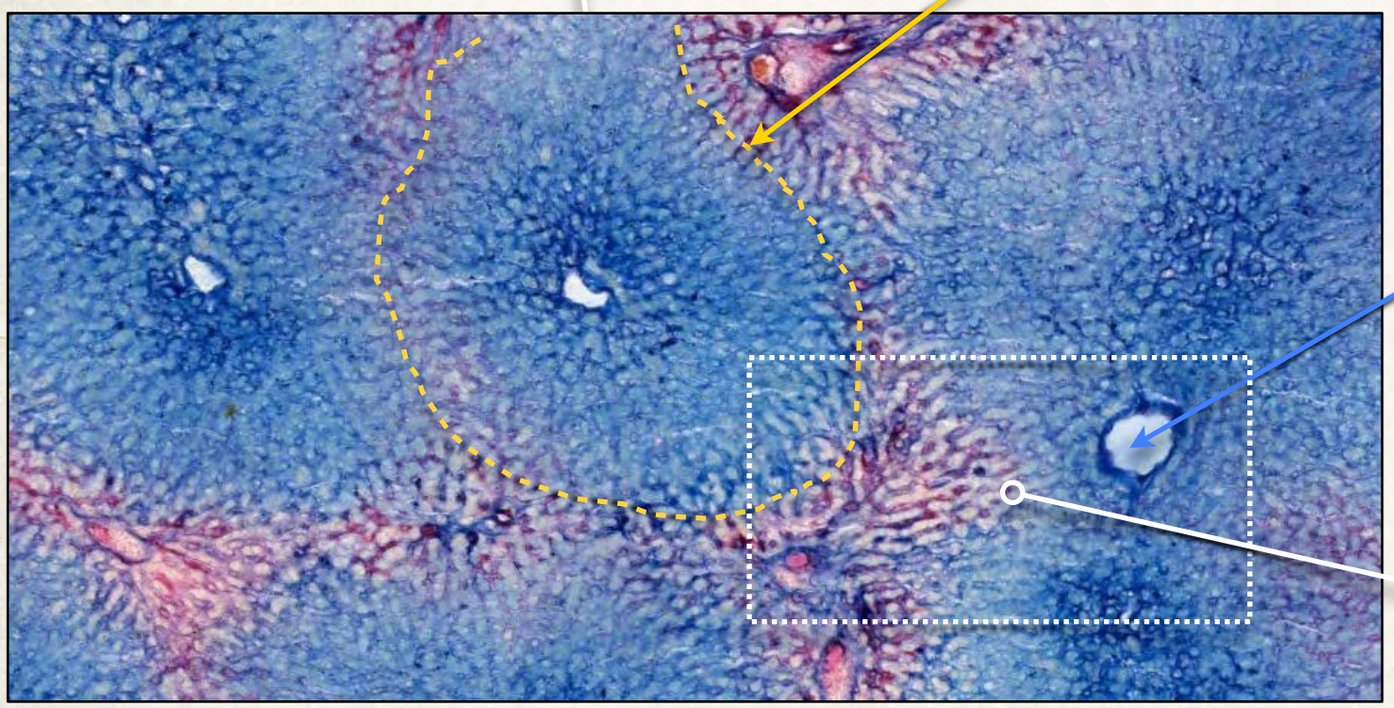

V. centralis

V. portae gren

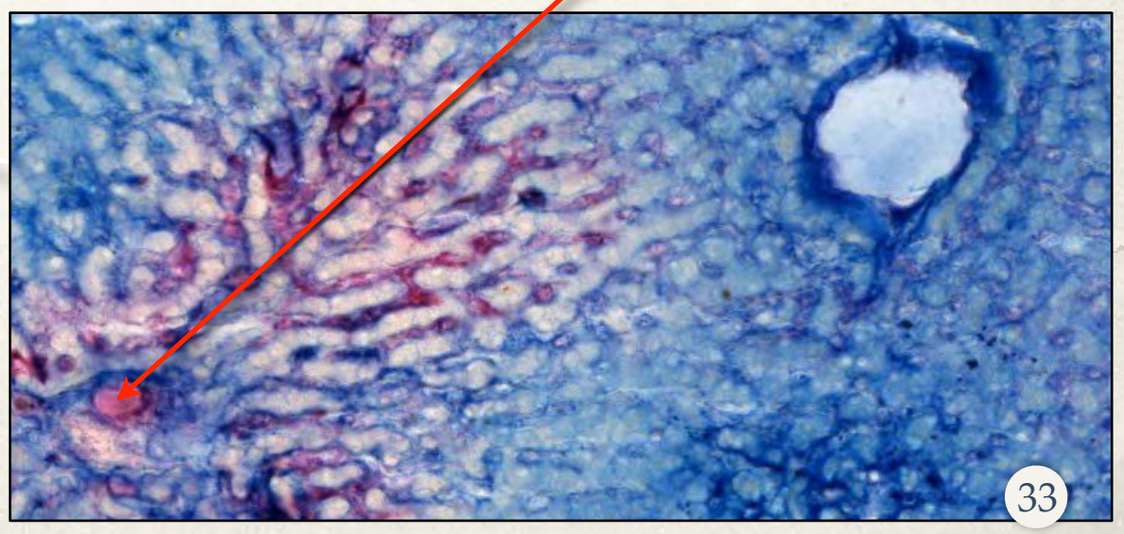

22. Lever med sinusioder

Siriusrød

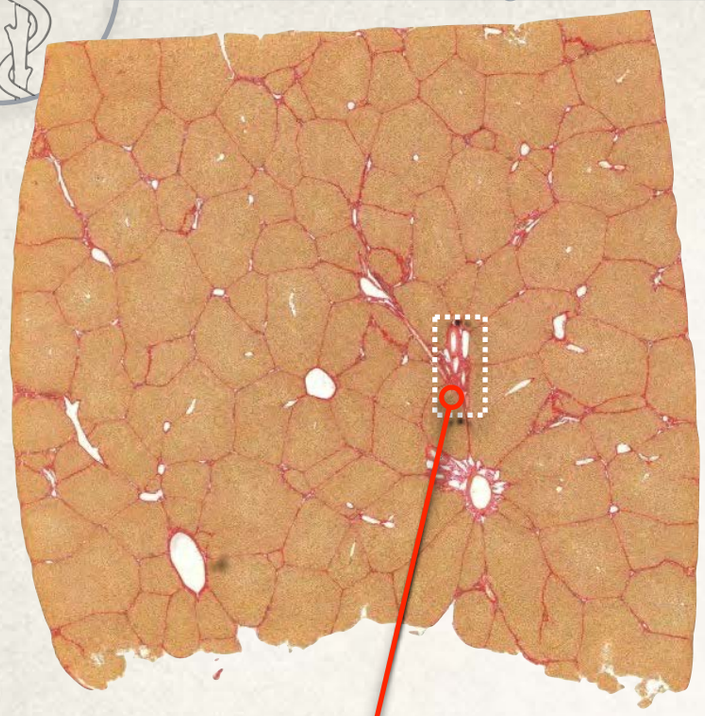

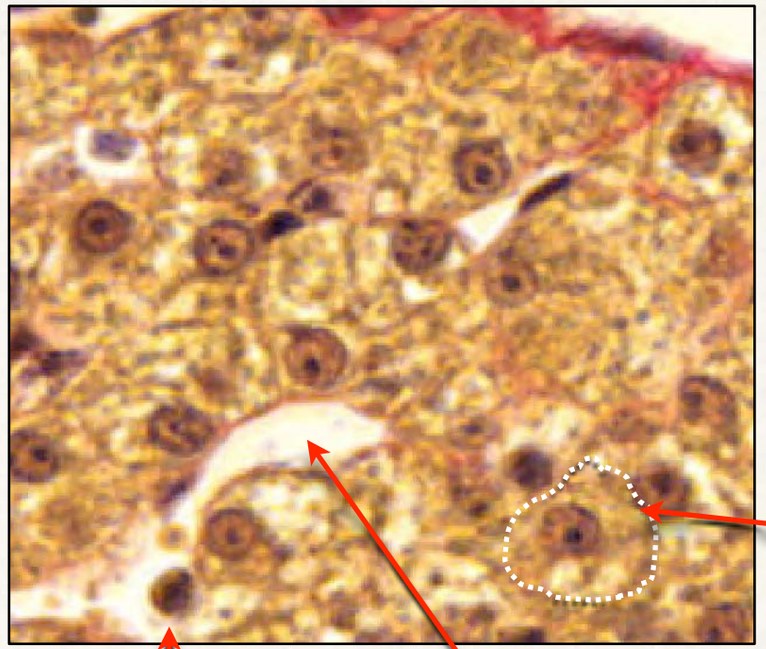

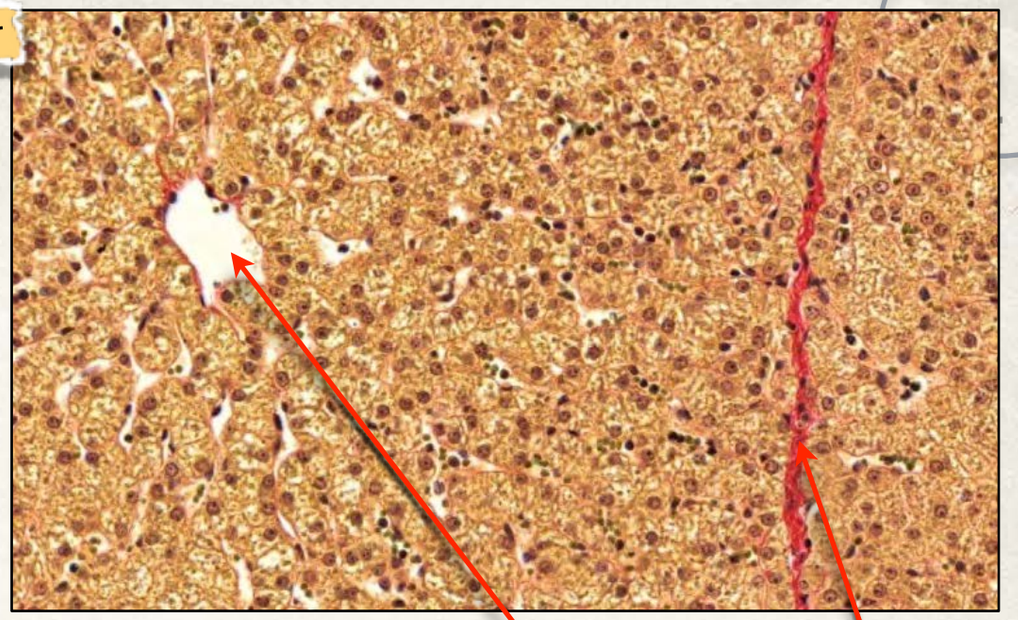

V. centralis

Hepatocyt

Interlobulært bindevæv

Makrofag

Sinusoide

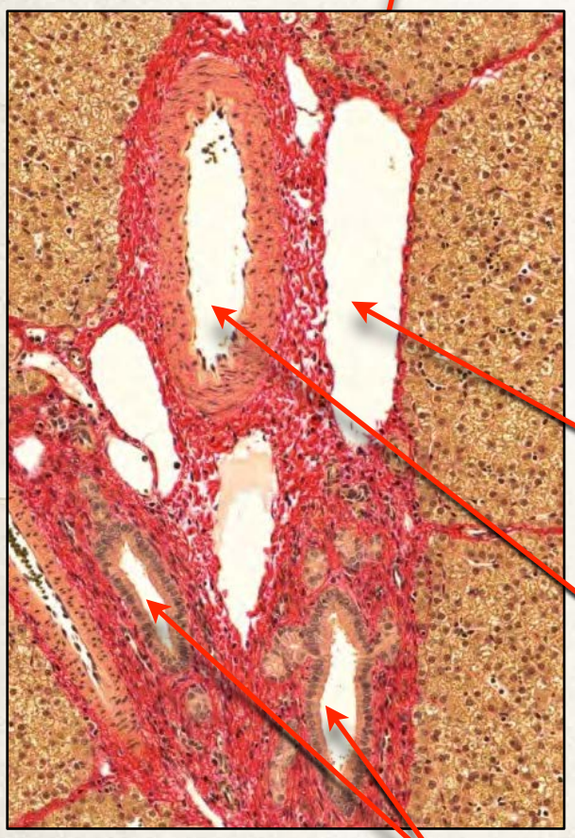

Gren fra v. porta
(Stor diameter og tynde væg)

Gren fra A. hepatica
(Bemærk den tykkere karvæg)

Galdegangsgren
(Enlagt kubisk epitel luminalt)

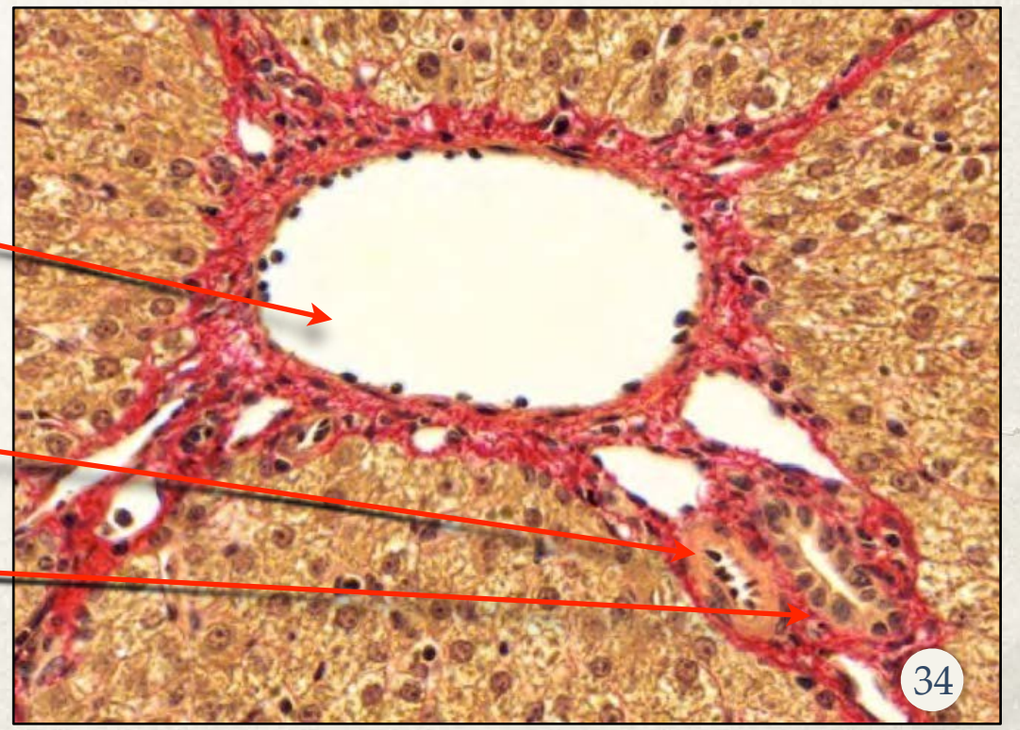

24. Glandula parotis

Siriusrød

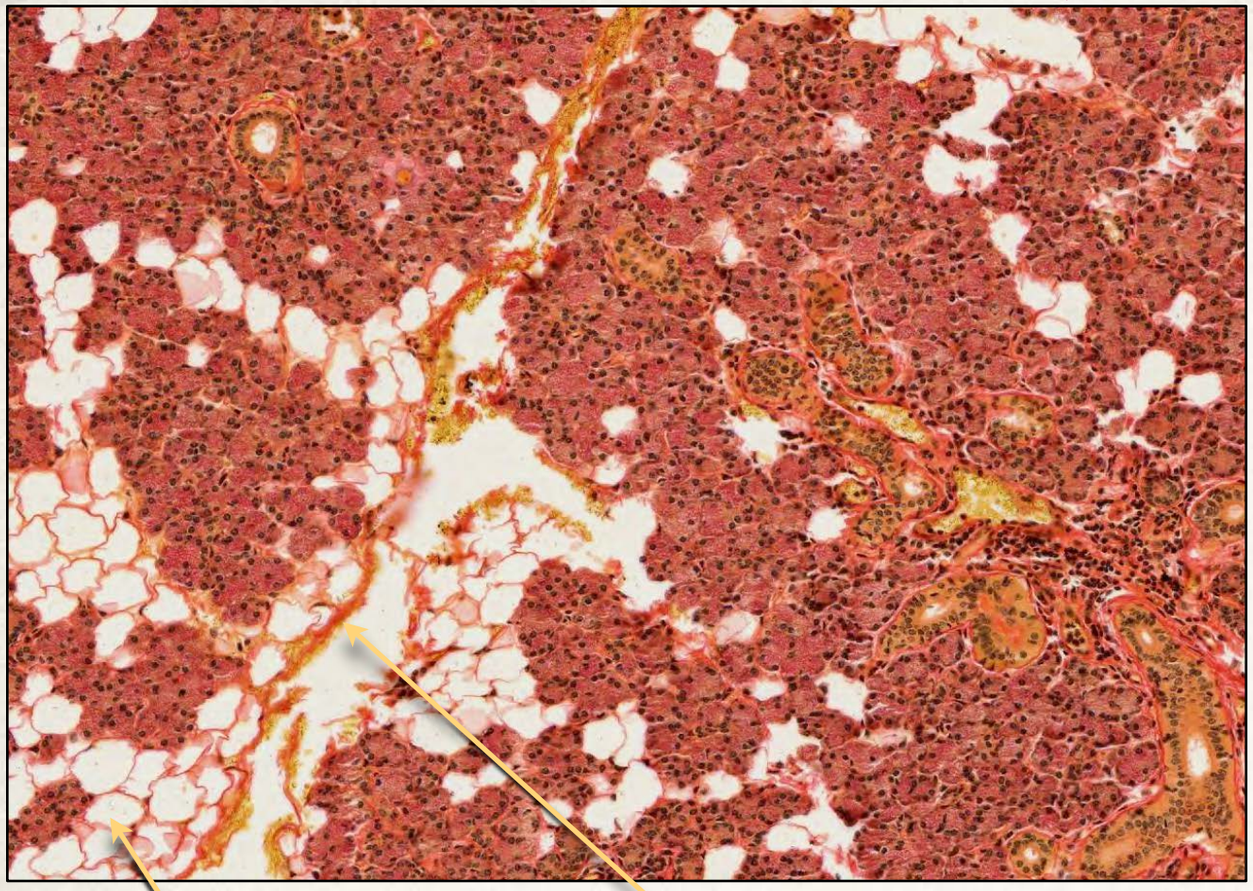

Fedt

Bindevævssepta

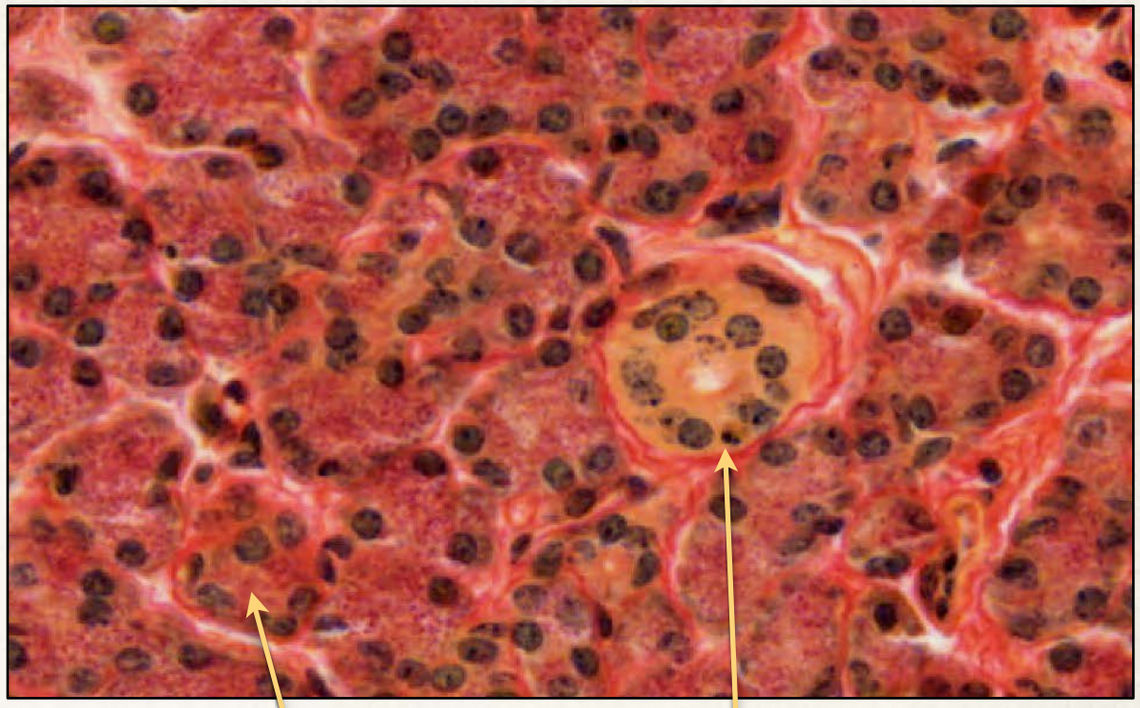

Serøst endestykke

Indskudsstykke
(Enlaget kubisk epithel)

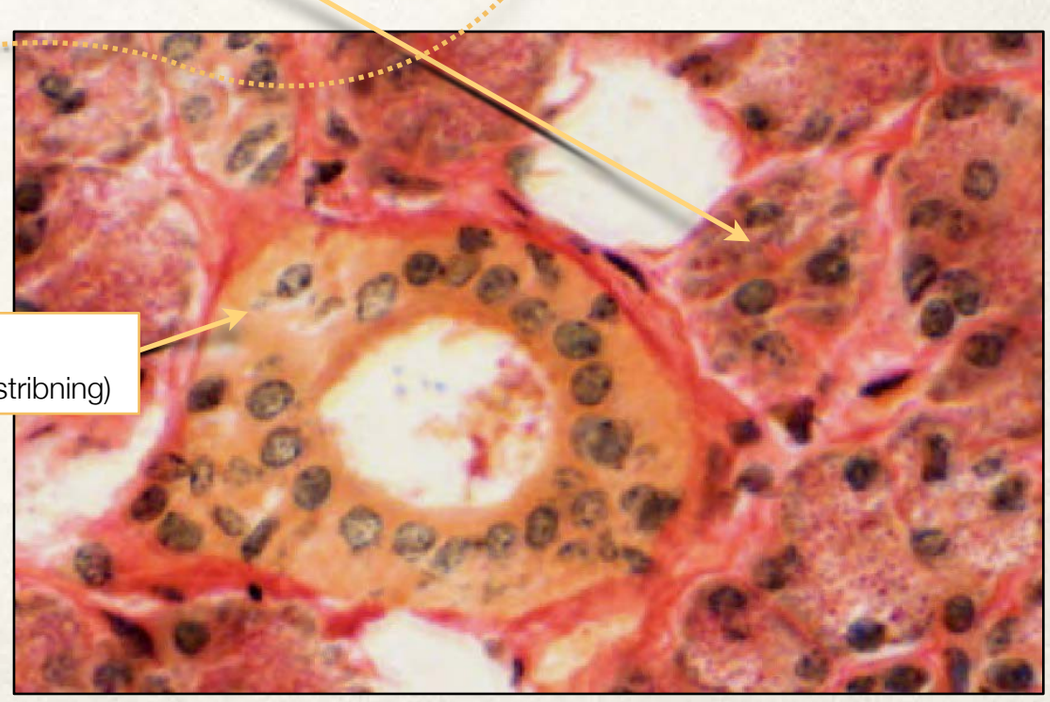

Spytrør
(Enlaget cylinderepithel med basalstribning)



25. Glandula submandibularis

Hæmatoxylin-Eosin

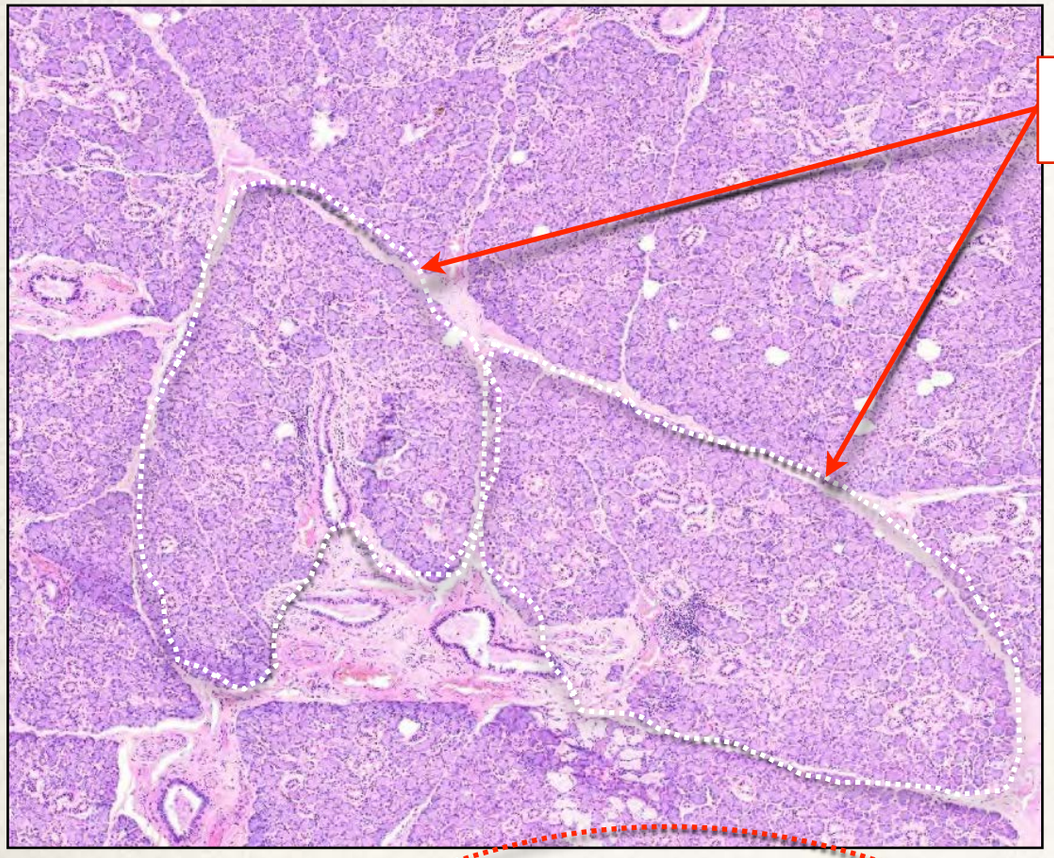

2 lobuli adskilt af interlobulært bindevæv

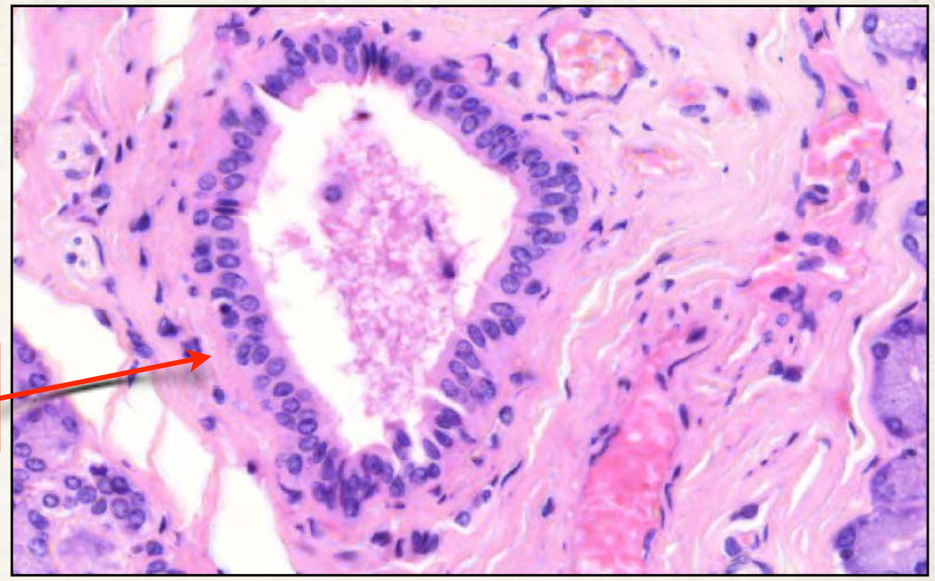

Interlobulær udførselsgang med bindevæv rundt om

Myoepitelial celle

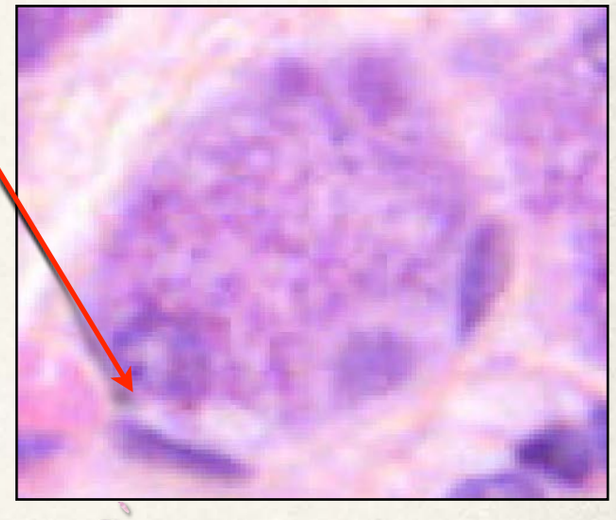

Serøst endestykke

Indskudsstykke

Mucøst endestykke



Serøst acinus



Mukøst acinus



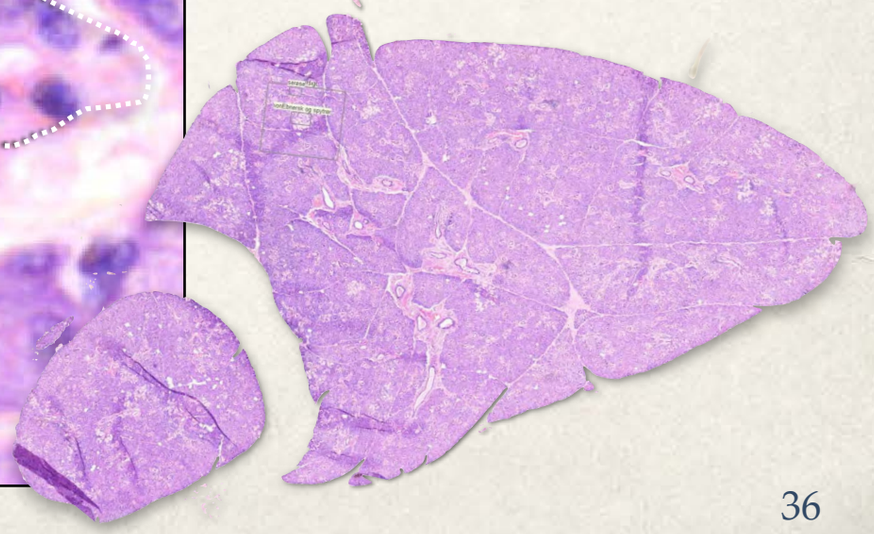

25A. Glandula submandibularis

PAS

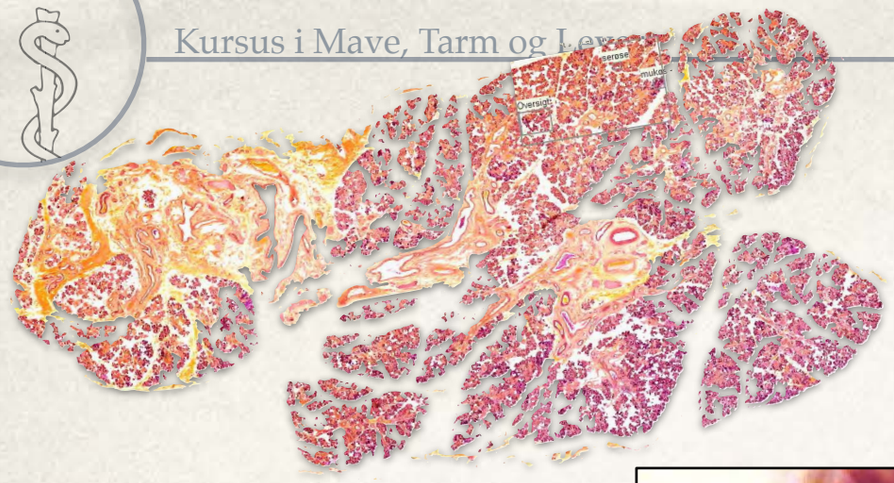



Spytrør

Mucøse endestykker

Venole

Serøse endestykker

26. Glandula sublingualis

Hæmatoxylin-Eosin

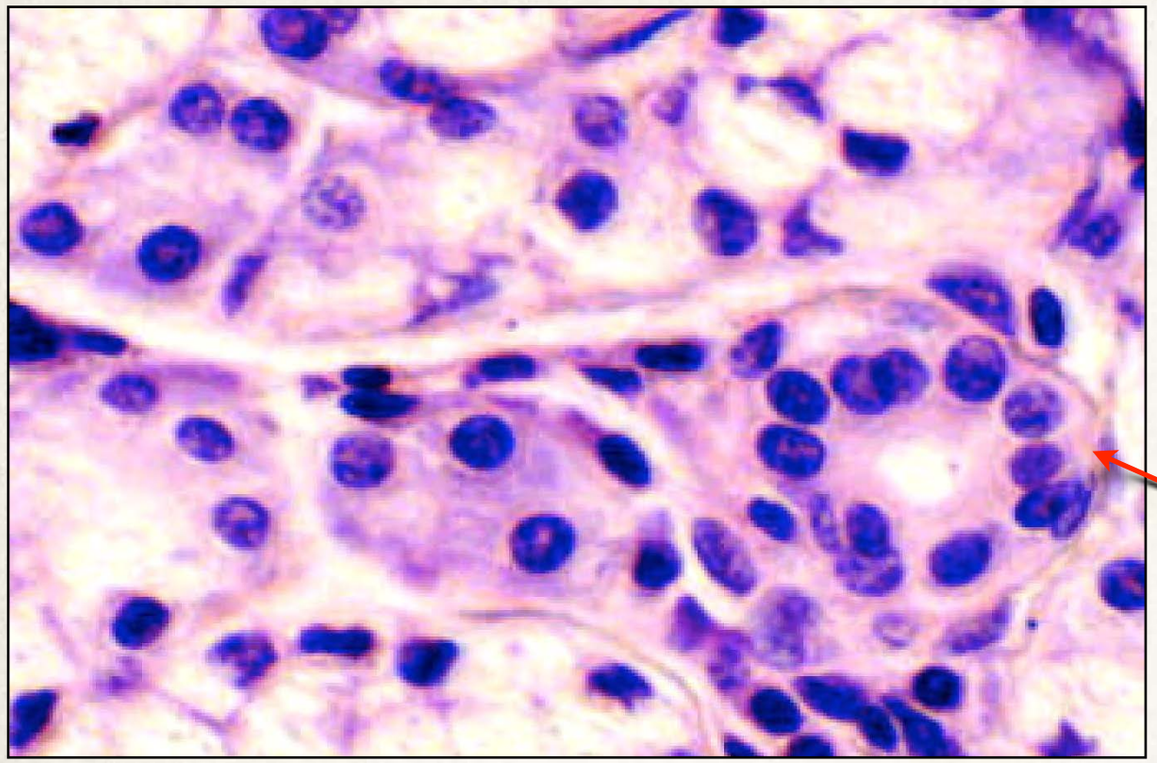

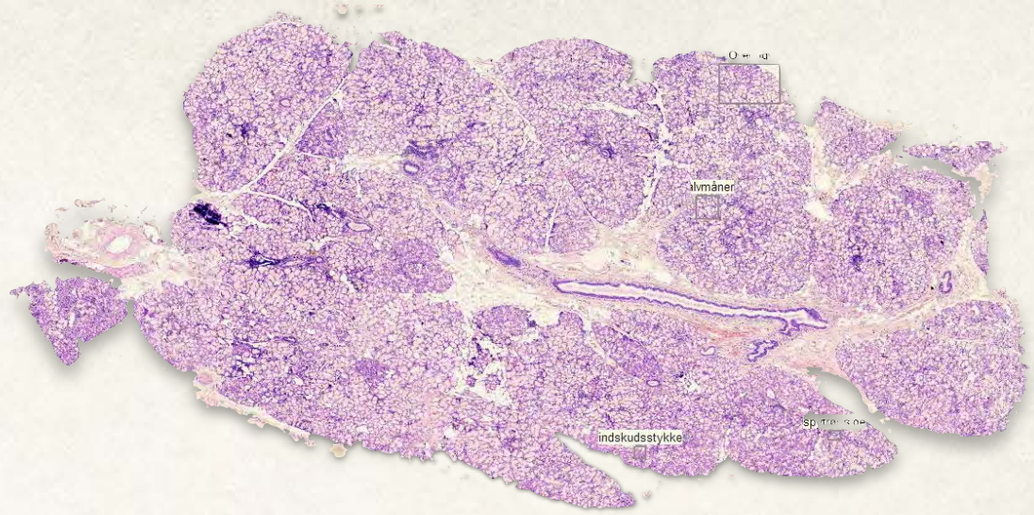

Indskudsstykke

Interlobær udførselsgang

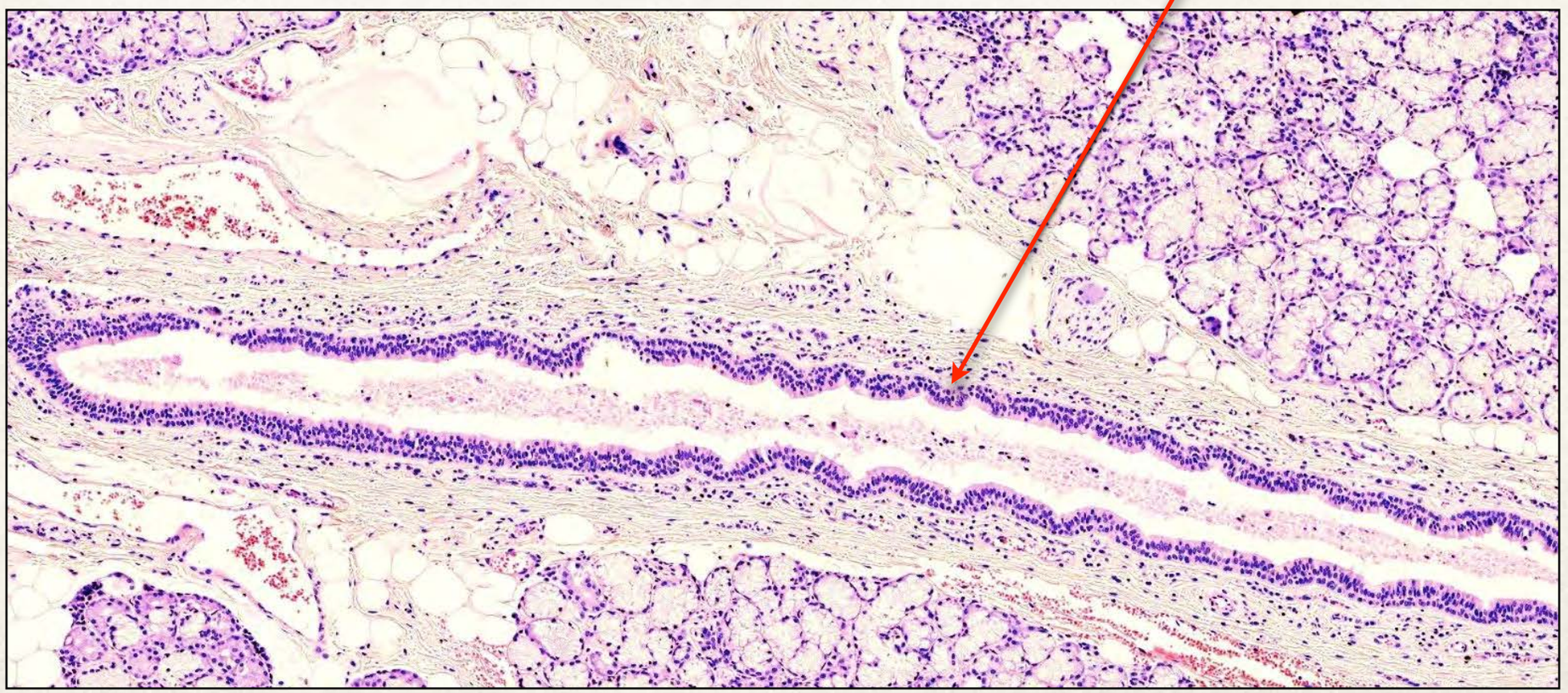

27. Pancreas

Hæmatoxylin-Eosin

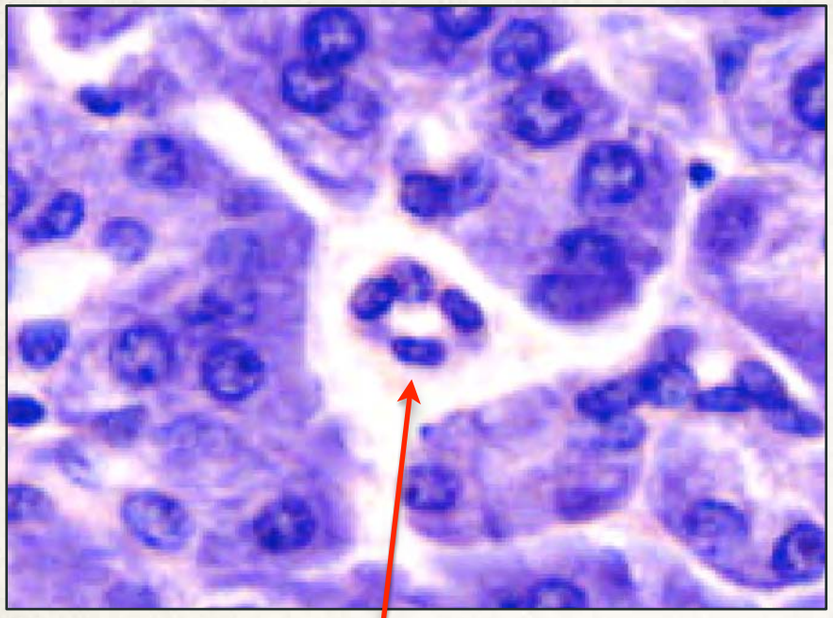

Indskudsstykke

Serøse acinære endestykker

Langerhannsk ø

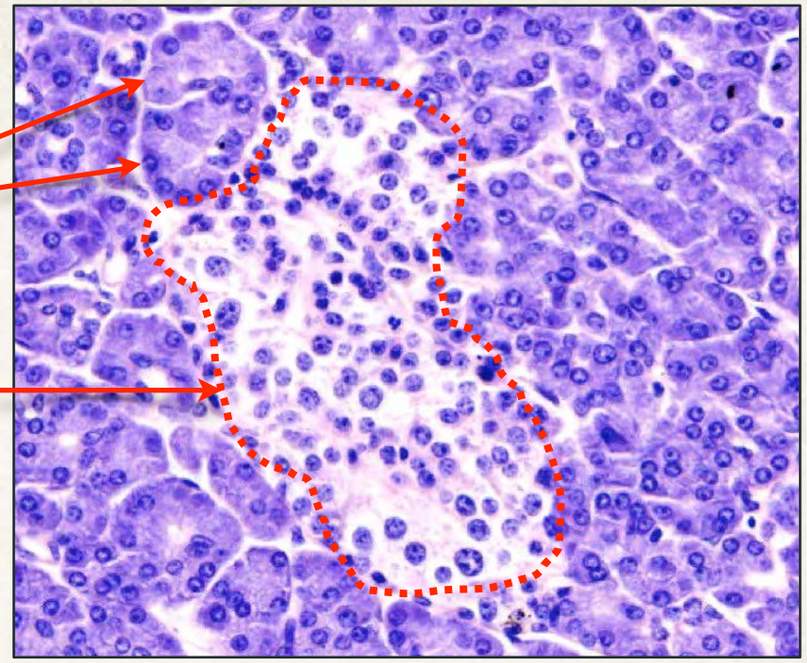

Interlobulær udførselsgang

Centroacinær celle

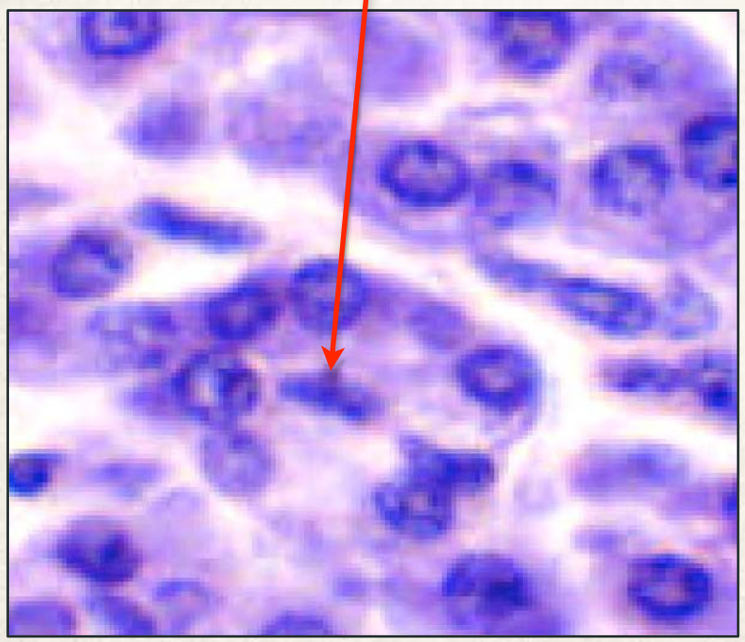

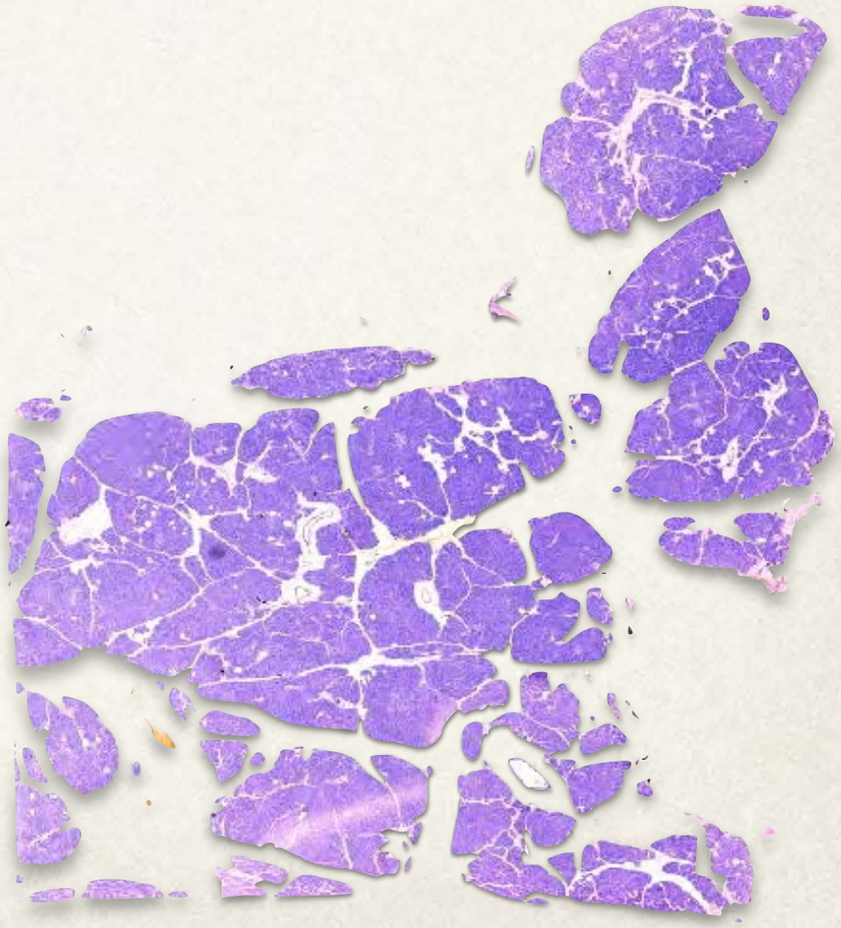

28. Insulin immunreaktion

Imunno-
histokemisk

Immunhistokemisk farvning for insulin:
Alle de brune celler er beta-celler, der producerer insulin.

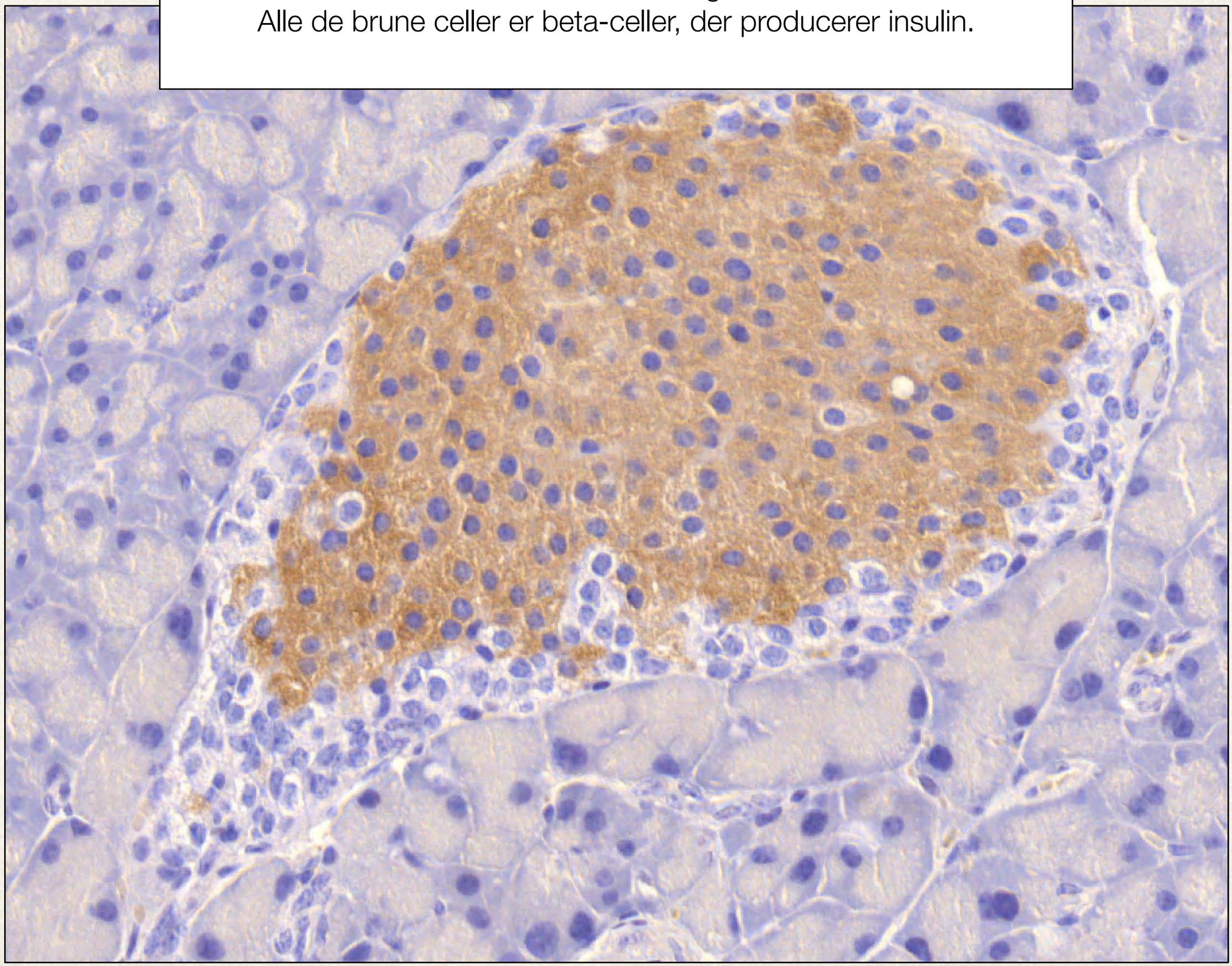

29. Glucagon immunreaktion

Imunno-
histokemisk

Immunhistokemisk farvning for glukagon:
Alle de brune celler er alfa-celler, der producerer glukagon.

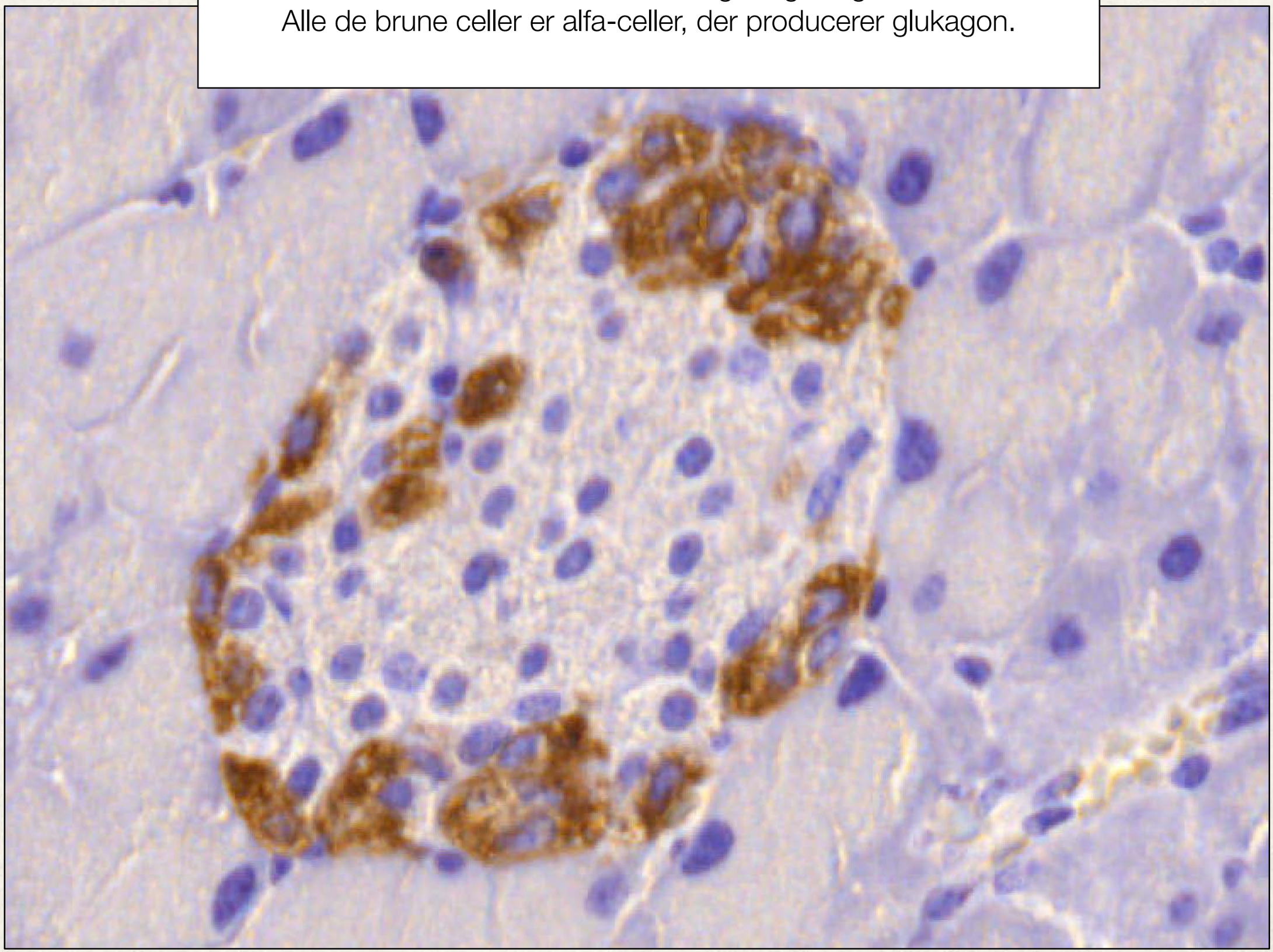

MIKROSKOPISK SPOTGUIDE

Hjertet

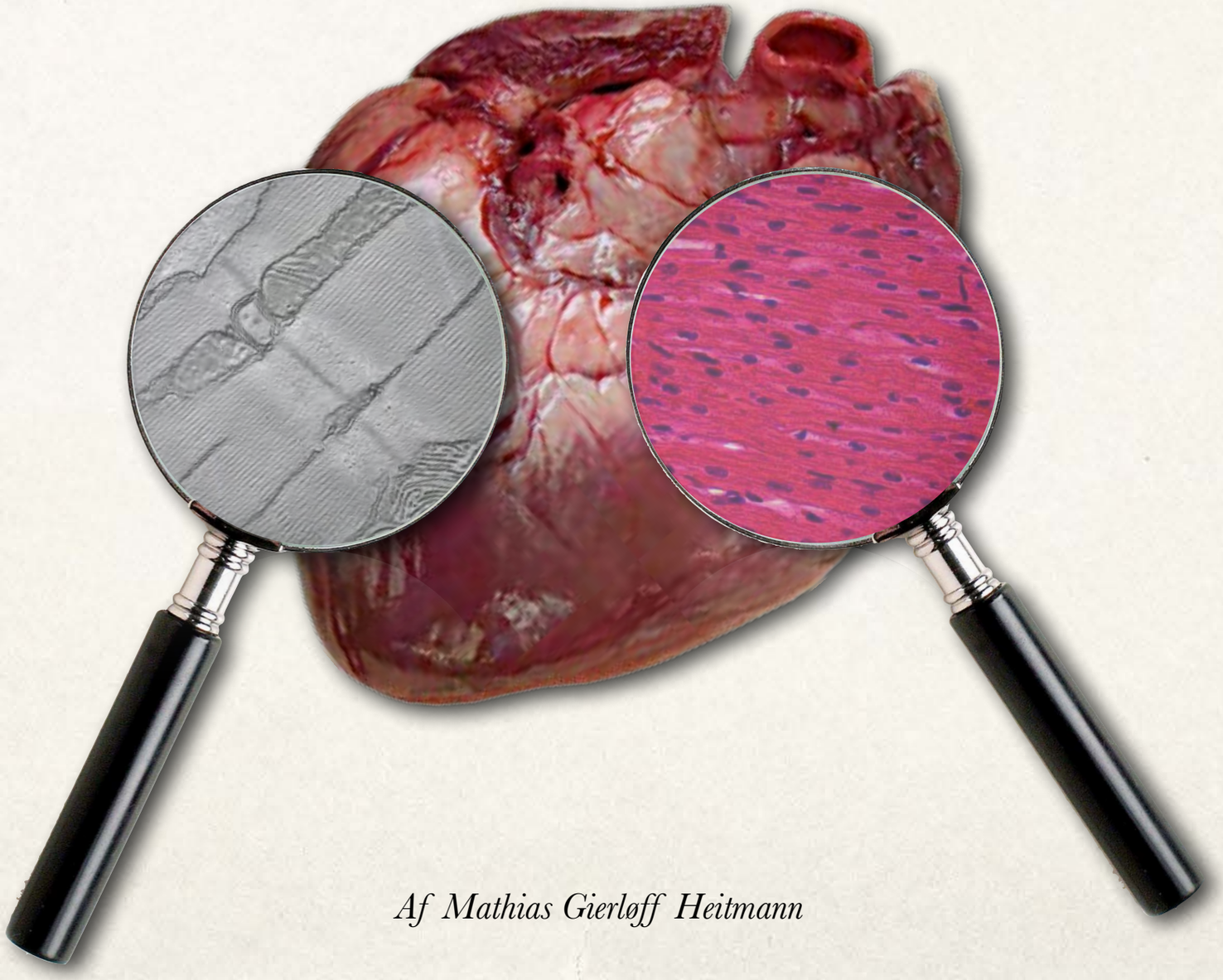

Af Mathias Gierløff Heitmann

36. Semilunærklap, Gris



37. Auricula dextra, Gris



38. Atrioventriculærknude, Gris



39. Septum interventriculare



39A. Septum interventriculare m. Hisske bundt, Gris



Godt at vide



Bindevævsfibre bliver røde

Muskulatur bliver gult

36. Semilunærklap, Gris

Siriusrød

Valvula semilunaris
"Poseklap"

Endocardium

Karlumen

Ventrikellumen

Ventriculus dexter

Glat muskulatur

Myocardium

Fedt

Truncus pulmonalis

Conus arteriosus

Epicardium
(Pericardium serosum lamina visceralis)

Valvula semilunaris
"Poseklap"

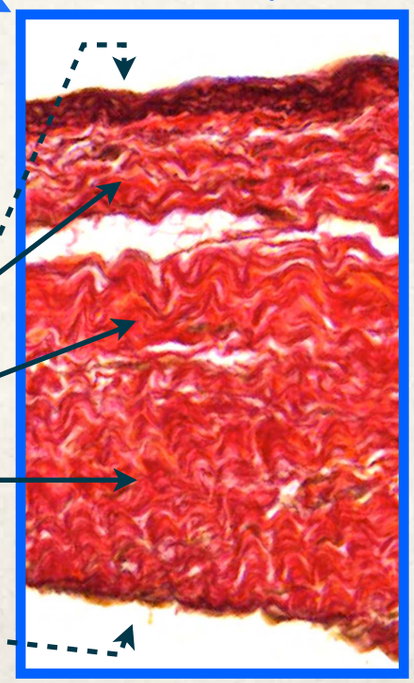

Tæt Fibrøst BV

Endocardium

= Præparatets afskårne kant

37. Auricula dextra, Gris

Siriusrød

= Præparatets afskårne kant

Cavitas pericardialis

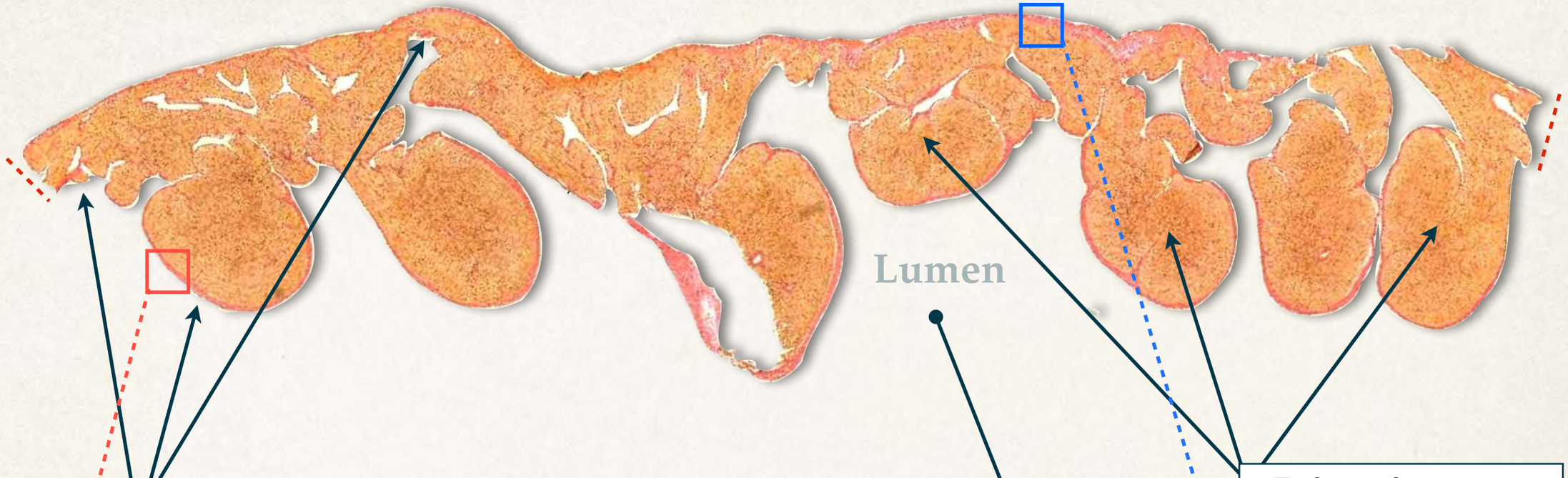

Lumen

Lumen af auriculus dexter + atrium dextrum

Trabecuale carneae
(Buler ind i lumen)

Endocardium

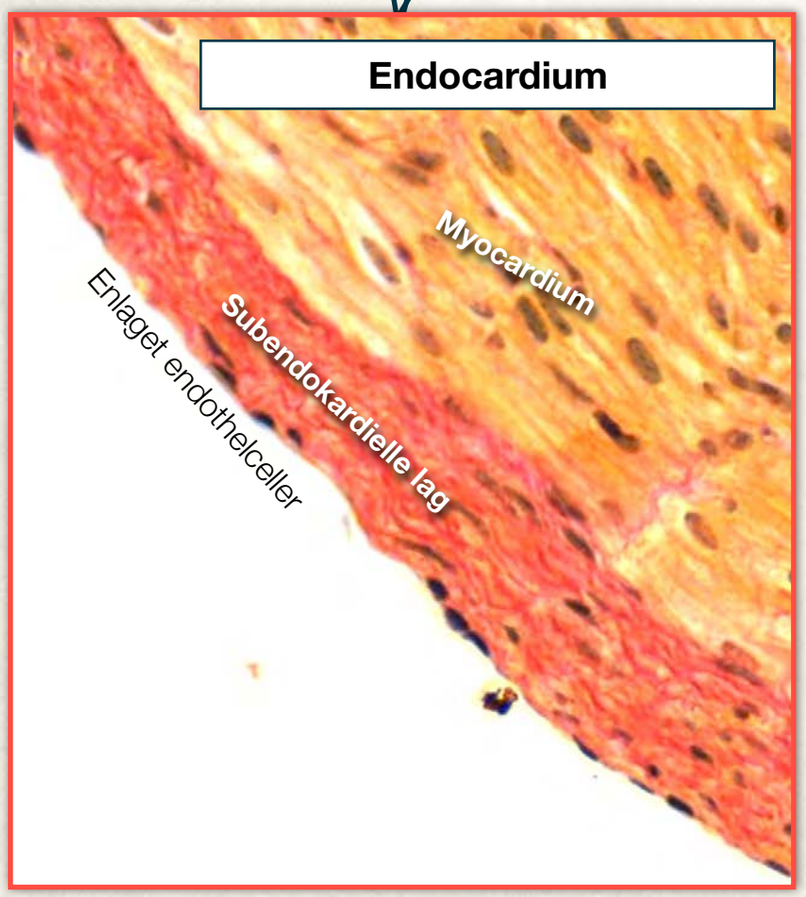

Epicardium
(Pericardium serosum lamina viscerale)

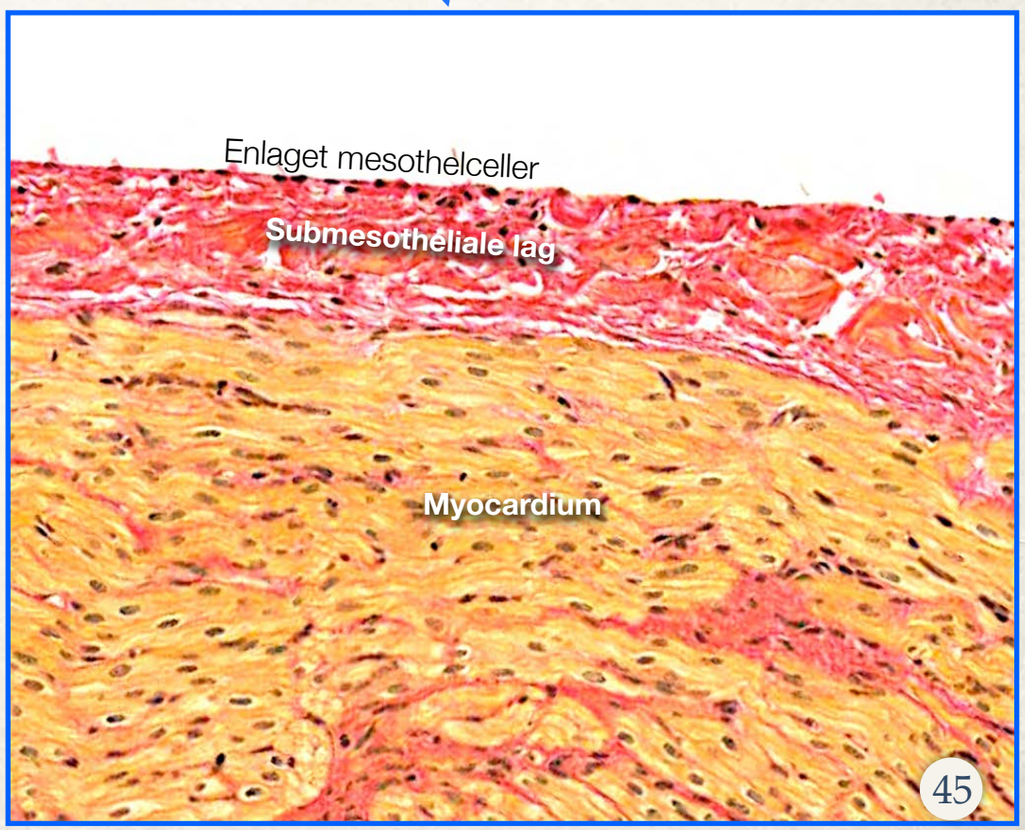

38. Atrioventriculærknude fra gris

Siriusrød

Overblik

Aorta ascendens

Sandsynligvis pericardium

Nodus atrioventricularis

Septum interventricularis
Pars muscularis

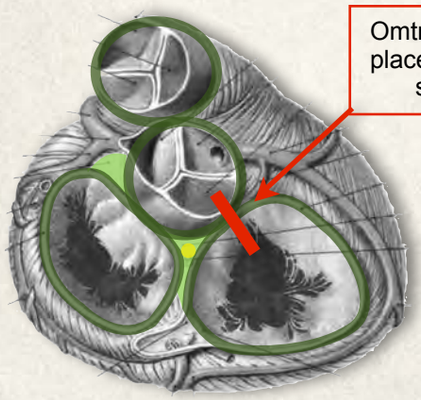

Cavitas pericardialis

Epicardium

Atrium dextrum

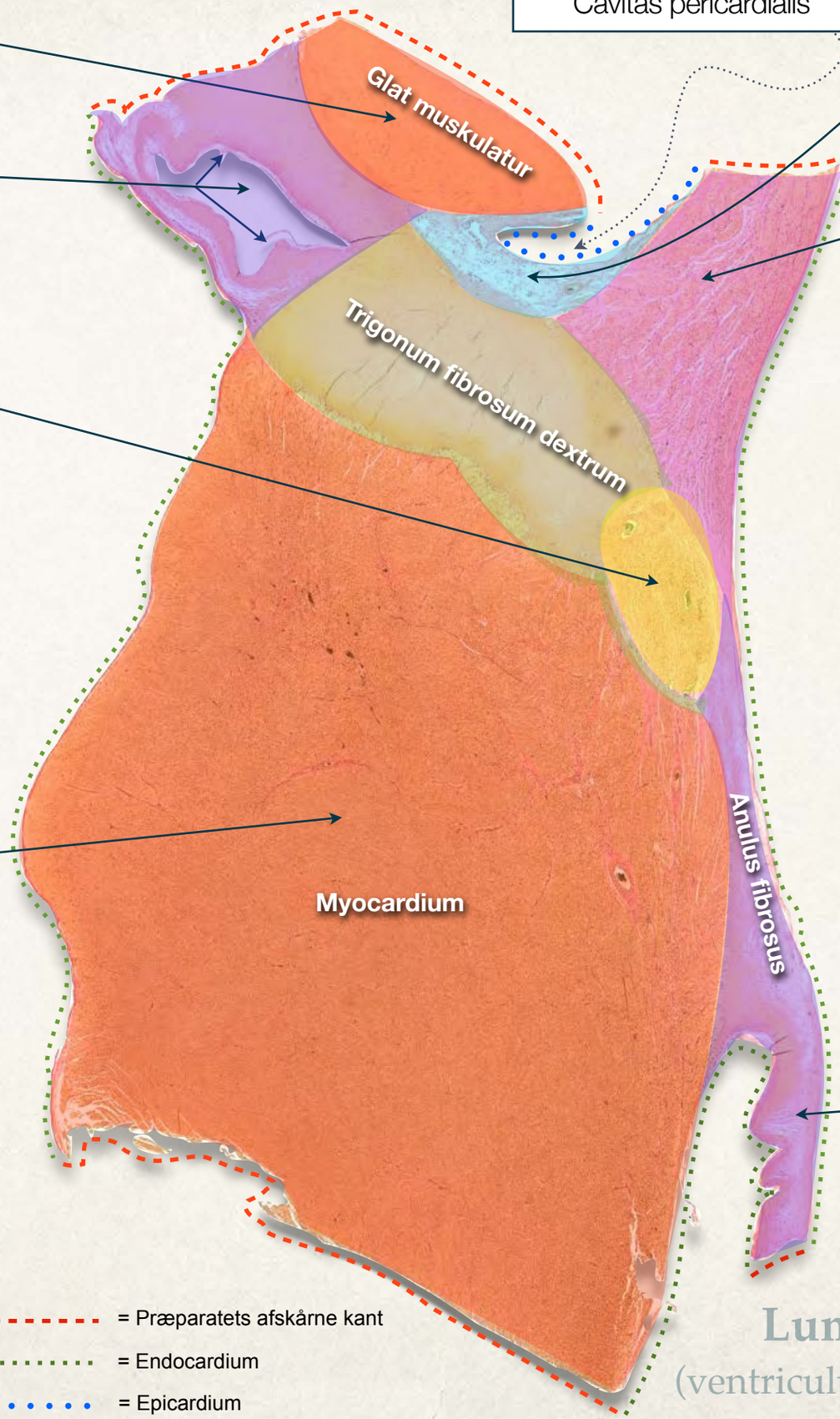

Lumen
(atrium dextrum)

Cuspis septalis /"Fligklap"
(Valva atrioventricularis dextra)

Lumen
(ventriculus dexter)

= Præparatets afskårne kant
= Endocardium
= Epicardium

38. Atrioventriculærknude fra gris

Siriusrød

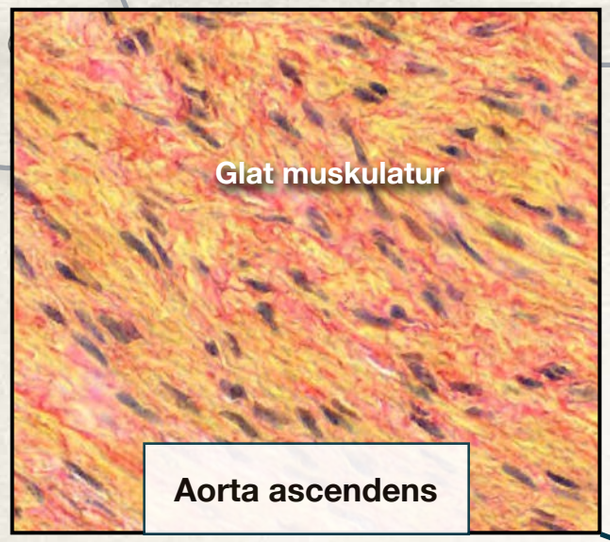

Aorta ascendens

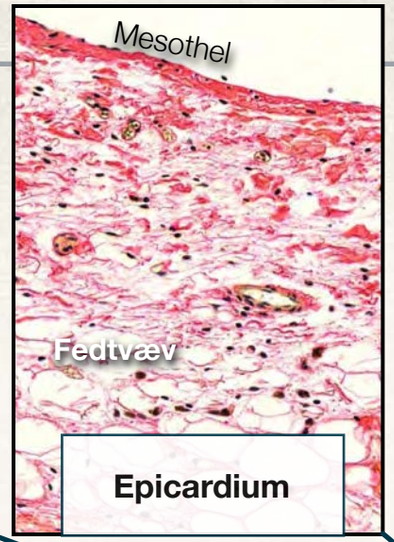

Epicardium

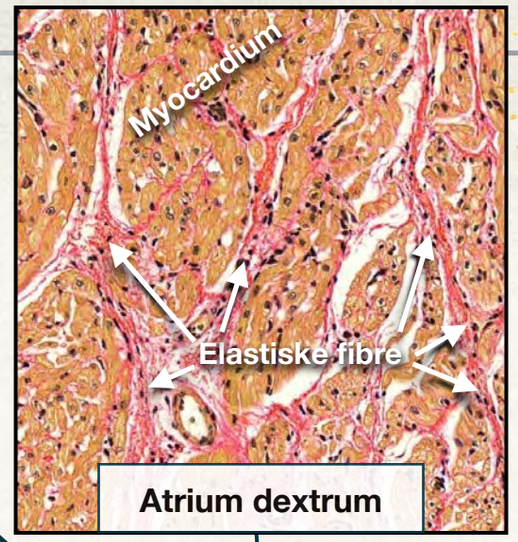

Atrium dextrum

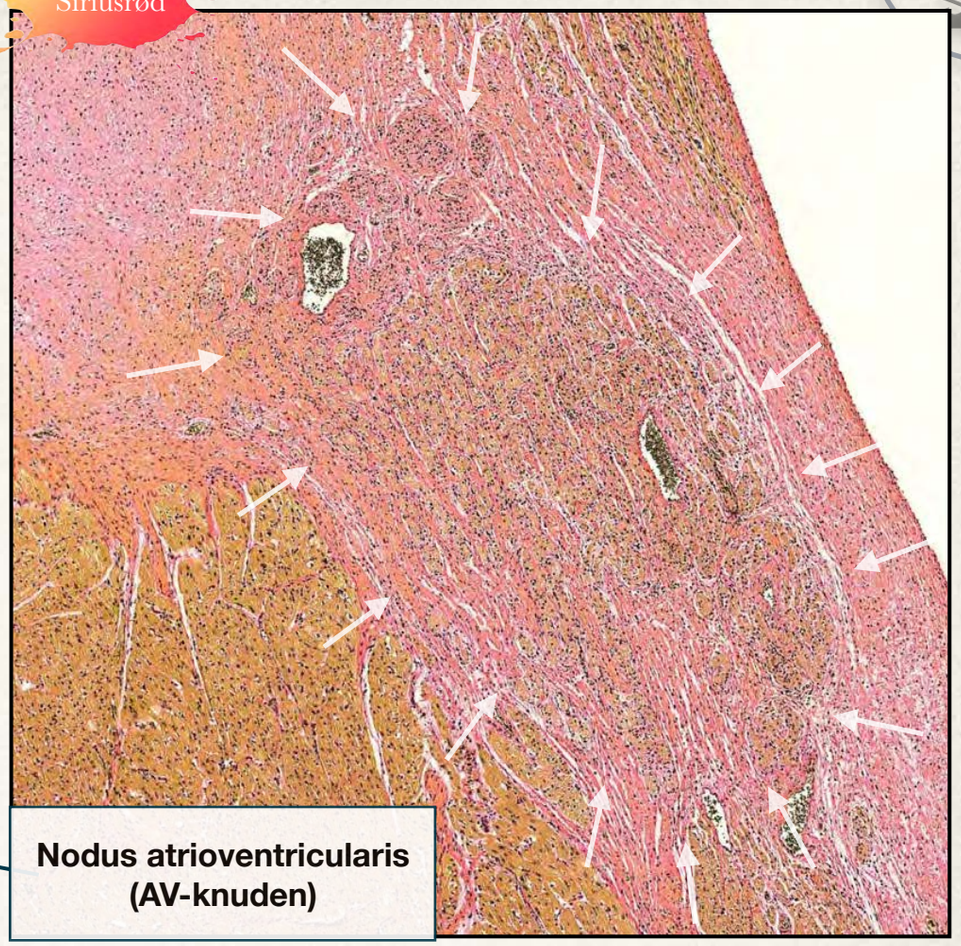

Nodus atrioventricularis
(AV-knuden)

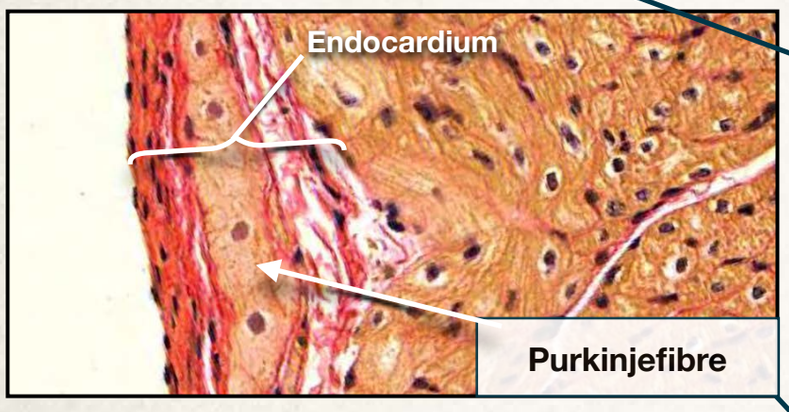

Purkinjefibre

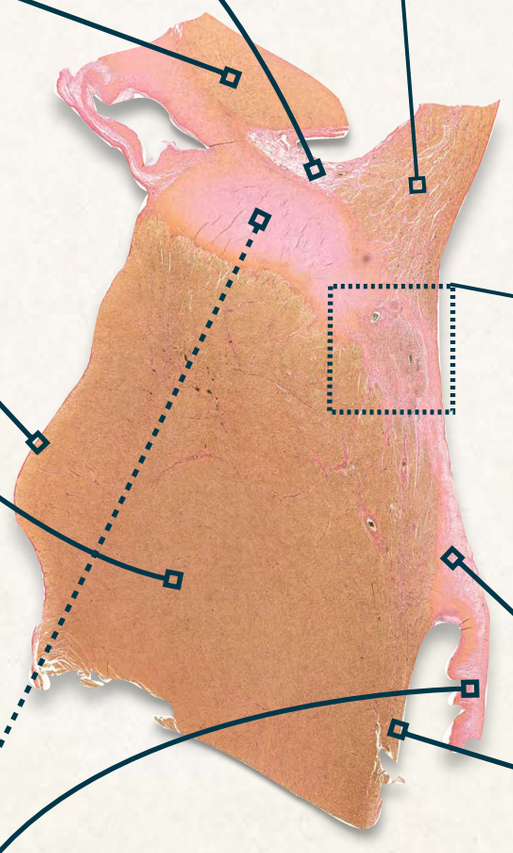

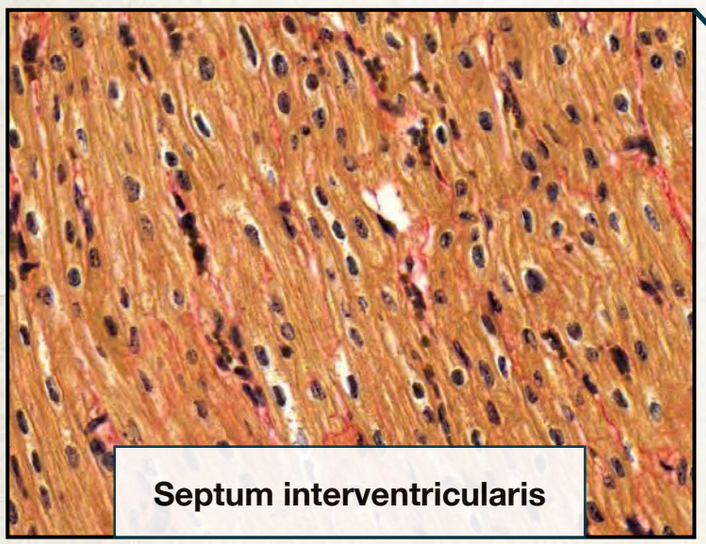

Septum interventricularis



Anulus fibrosus dexter

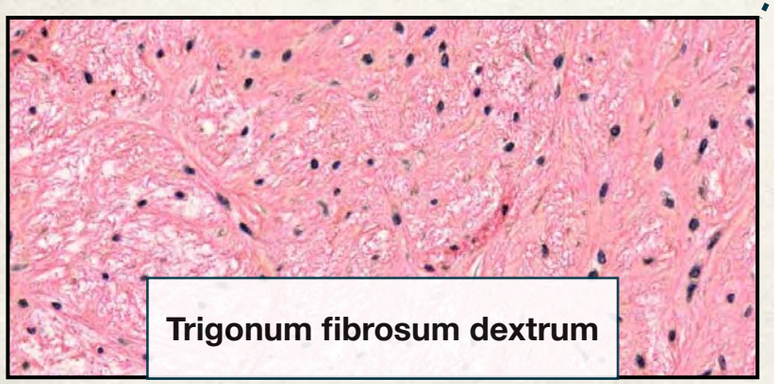

Trigonum fibrosum dextrum

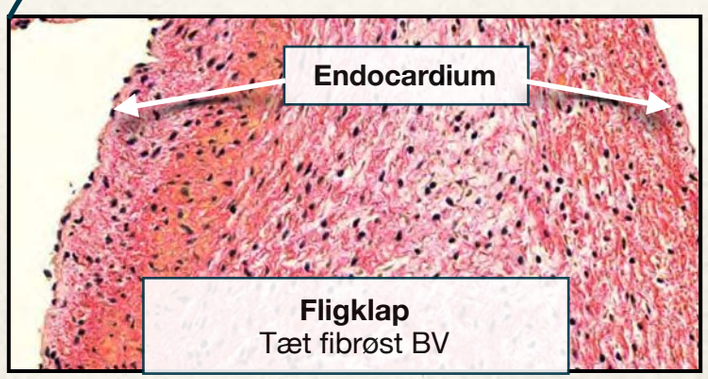

Fligklap
Tæt fibrøst BV

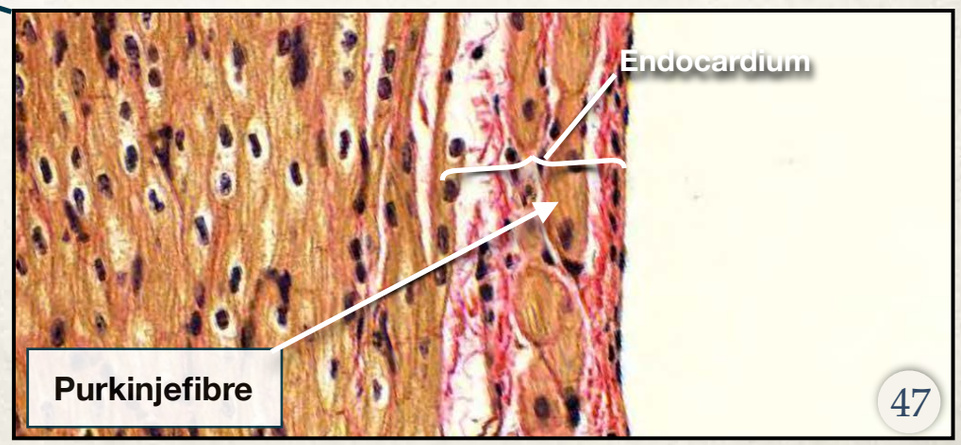

Purkinjefibre

38. Atrioventriculærknude fra gris

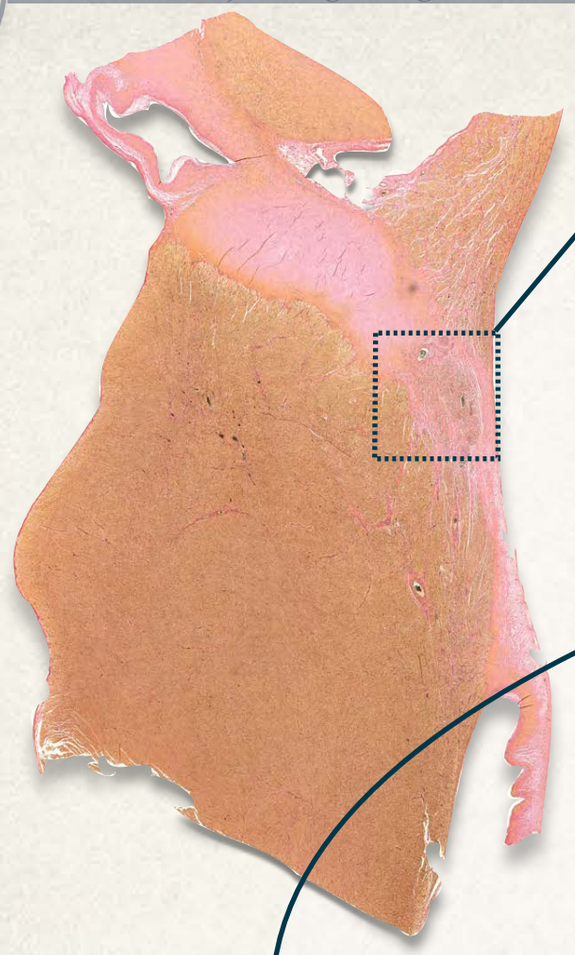

Siriusrød

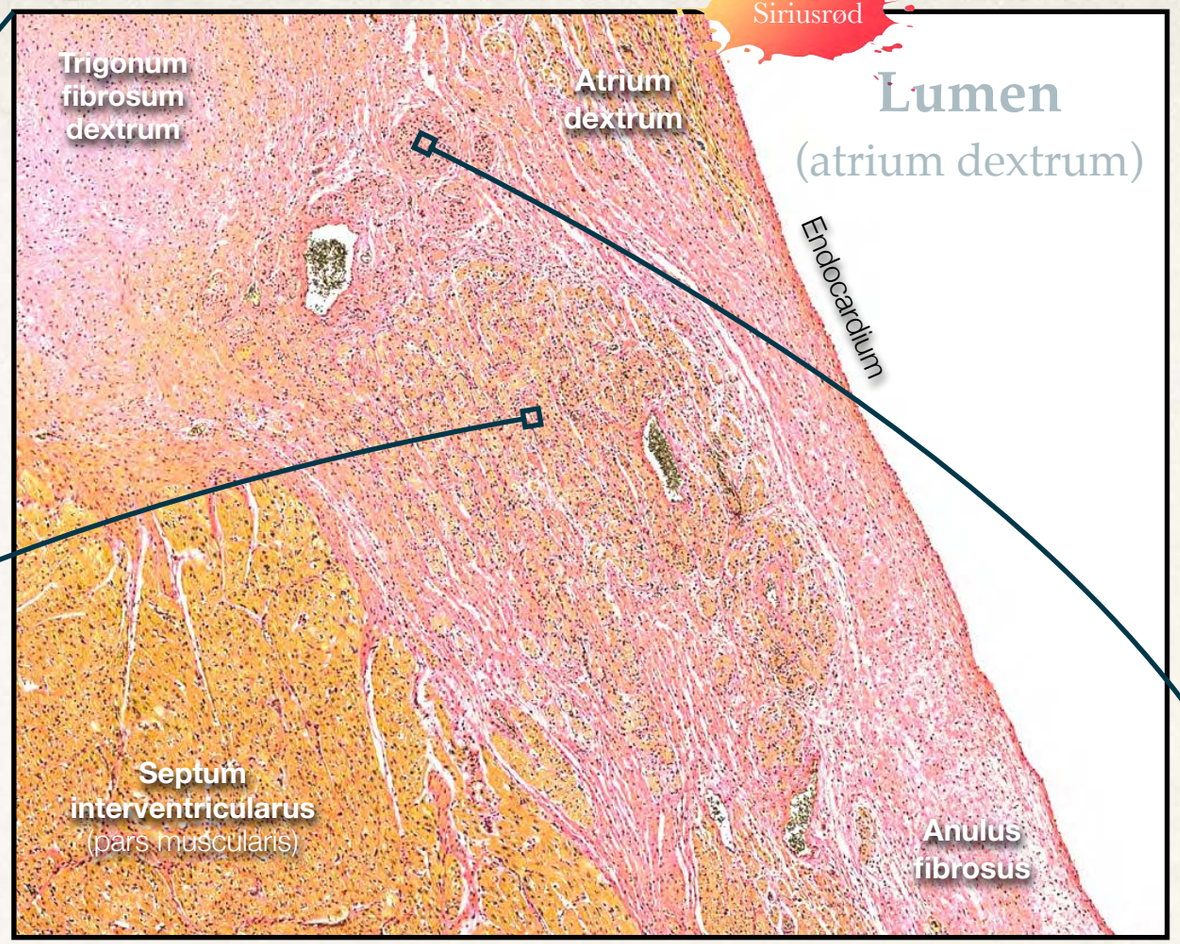

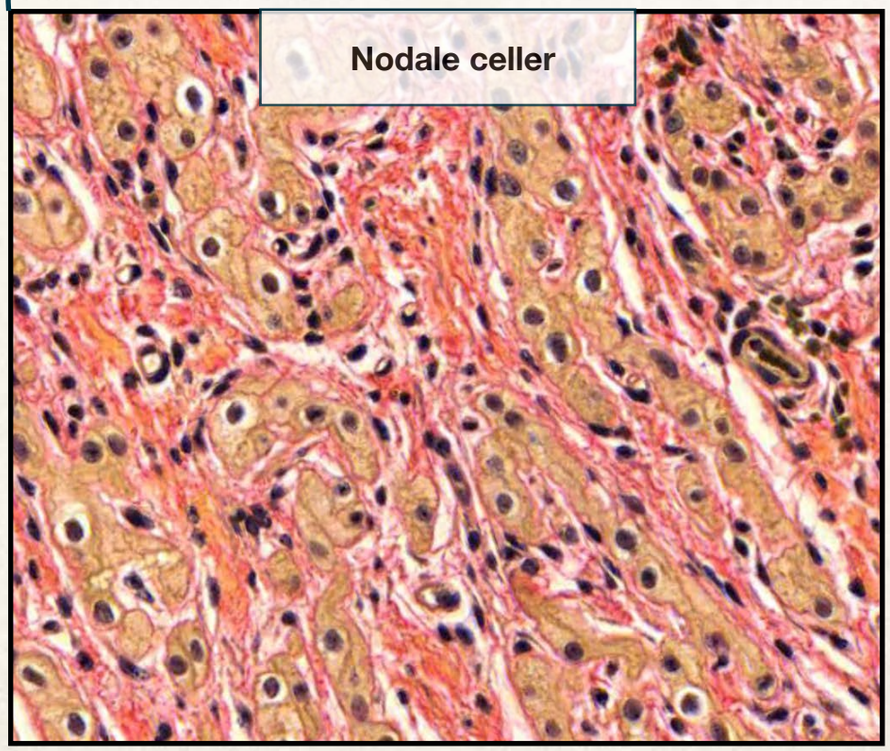

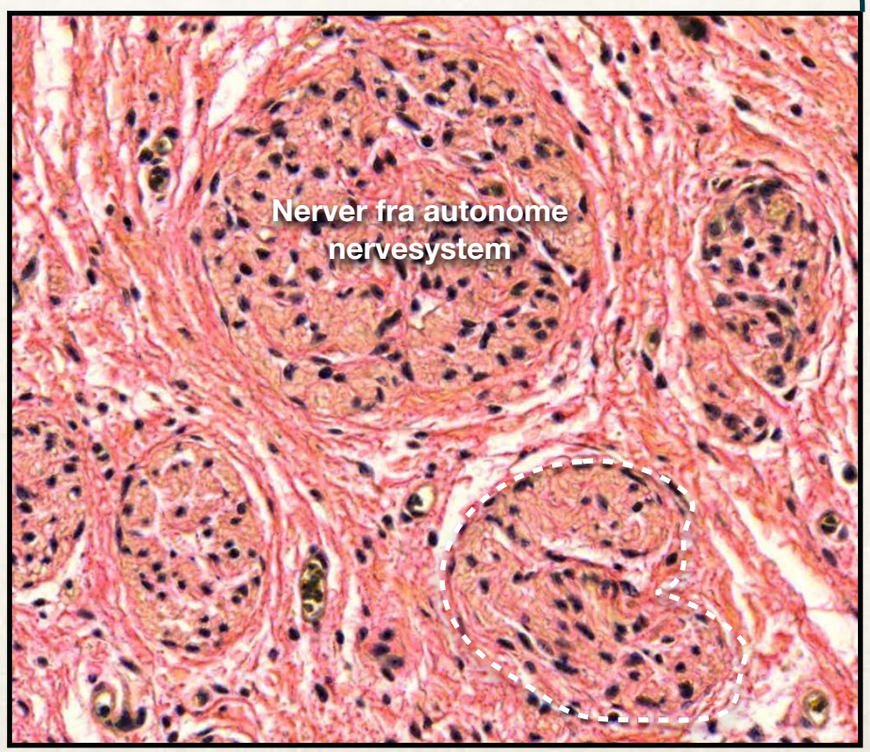

39. Septum interventriculare

Hæmatoxylin-Eosin

Septum interventricularus
(pars muscularis)

Lumen
(ventrikel)

Endocardium

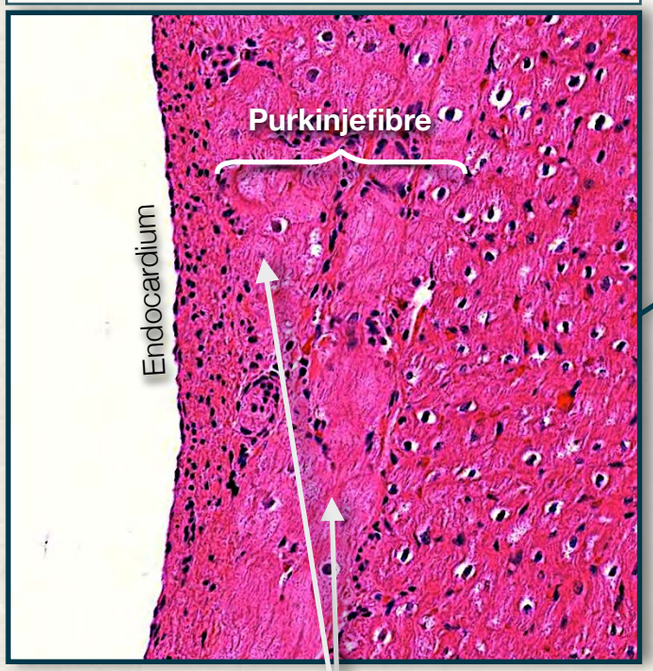

Purkinjefibre

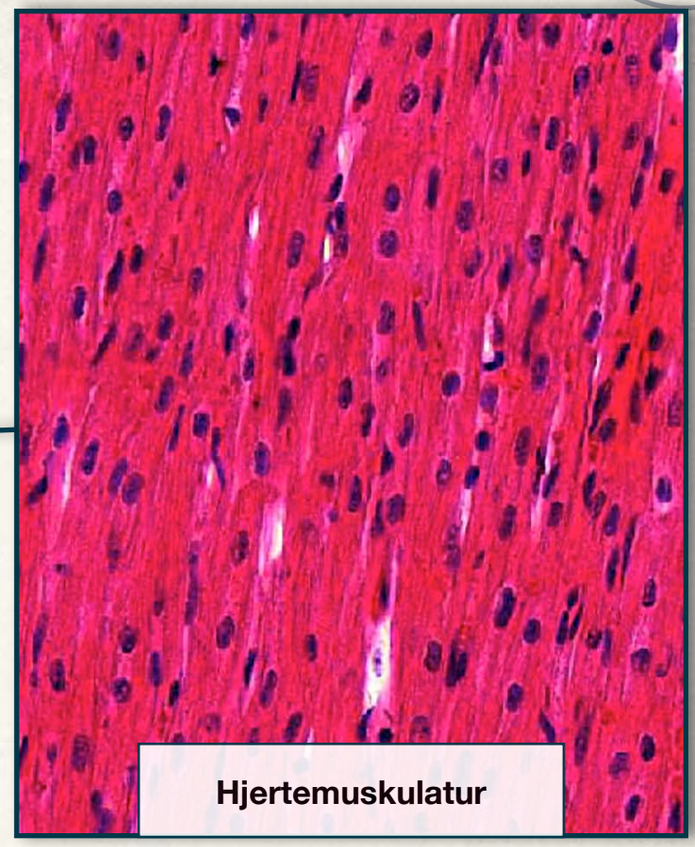

Hjertemuskulatur

Lumen

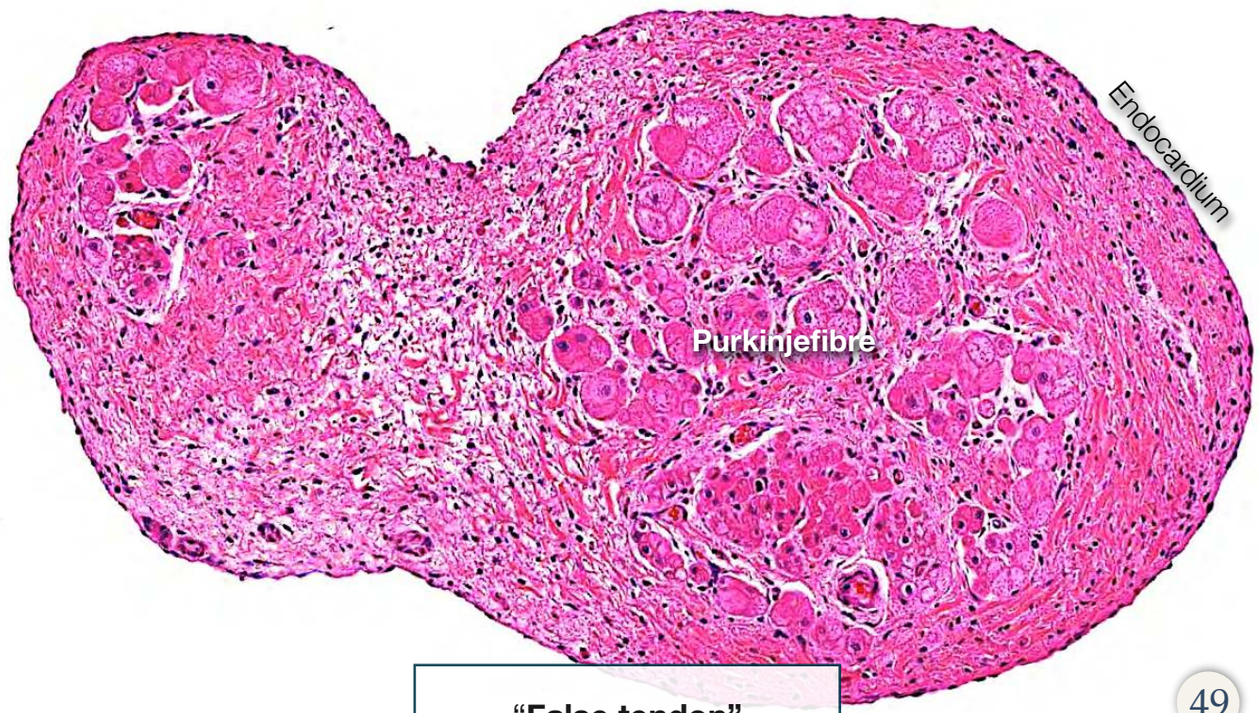

"False tendon"

= Præparatets afskårne kant

39A. Septum interventriculare m. Hisske bundt, Gris

Siriusrød

Overblik

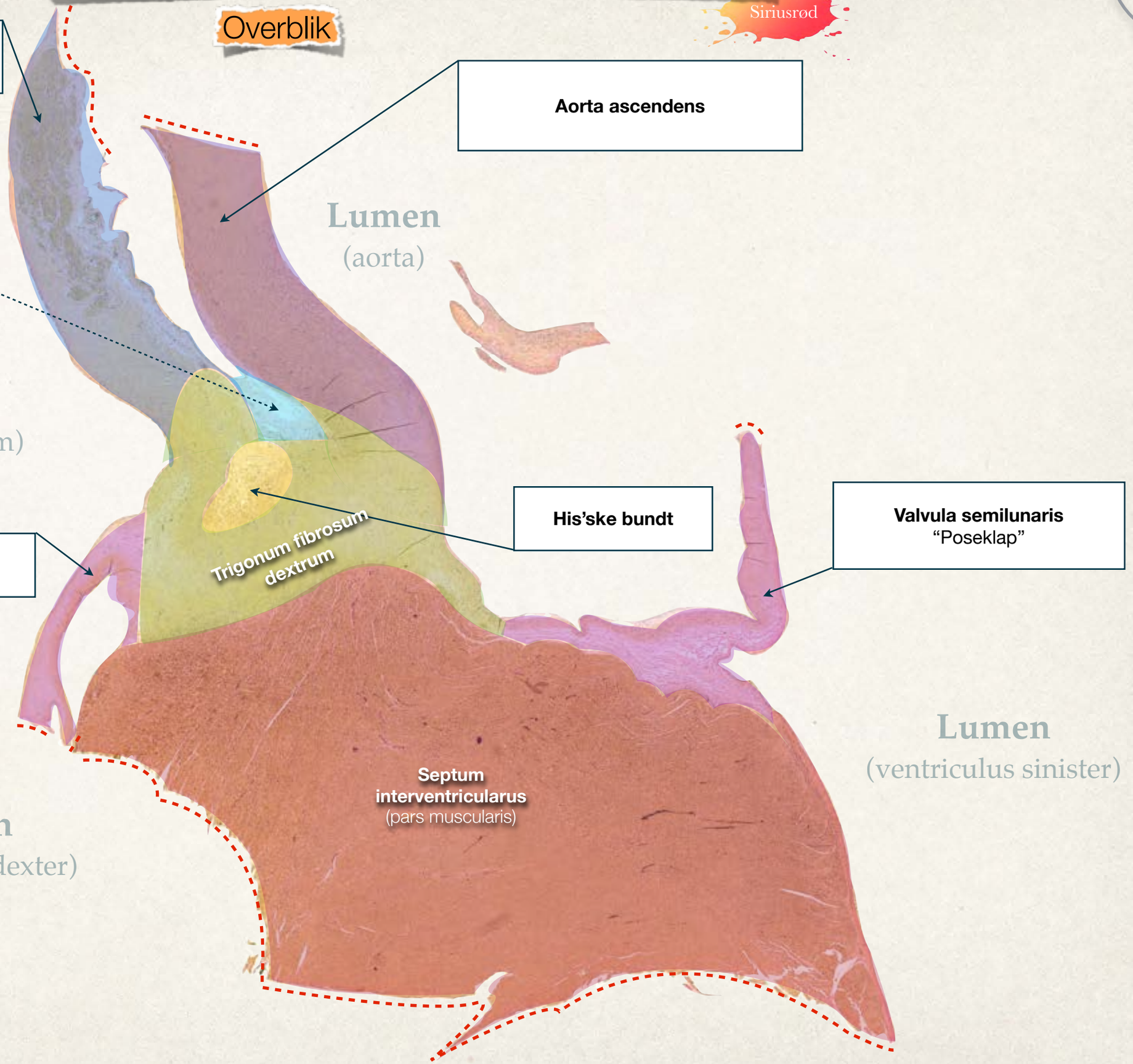

= Præparatets afskårne kant

OBS: Skråt snit
Overvej det i forhold til figur 18-5 i "Hoved-hals-bogen"

39A. Septum interventriculare m. Hisske bundt, Gris

Siriusrød

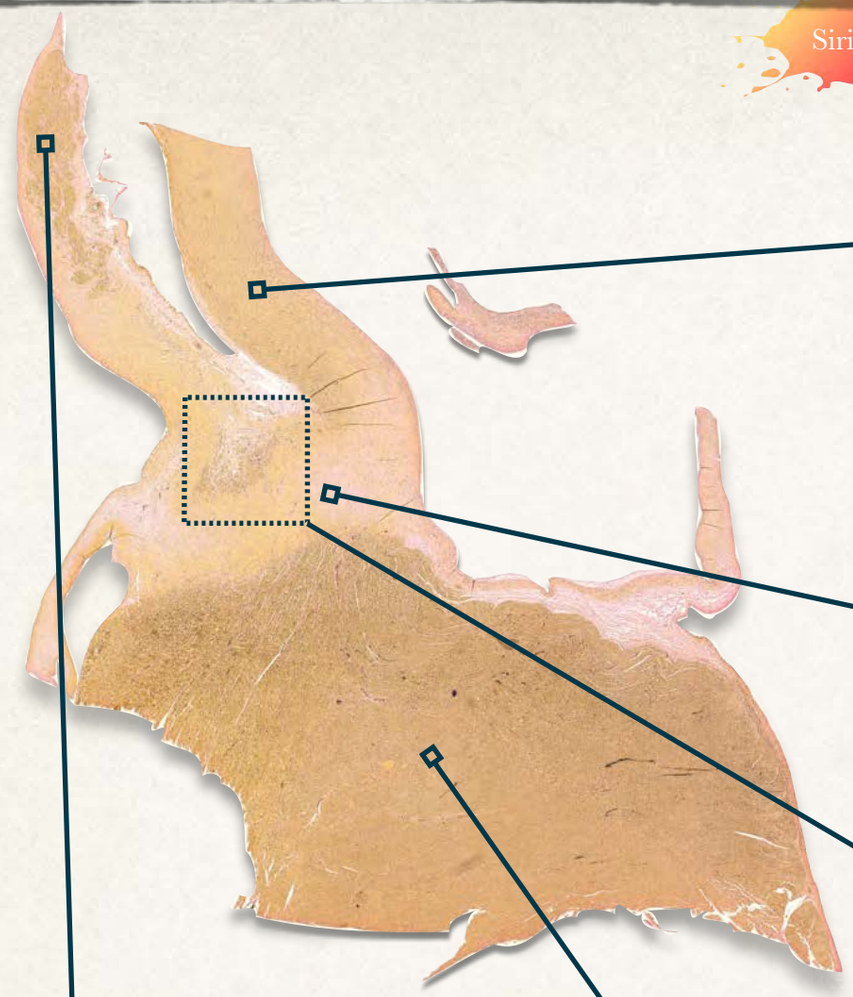

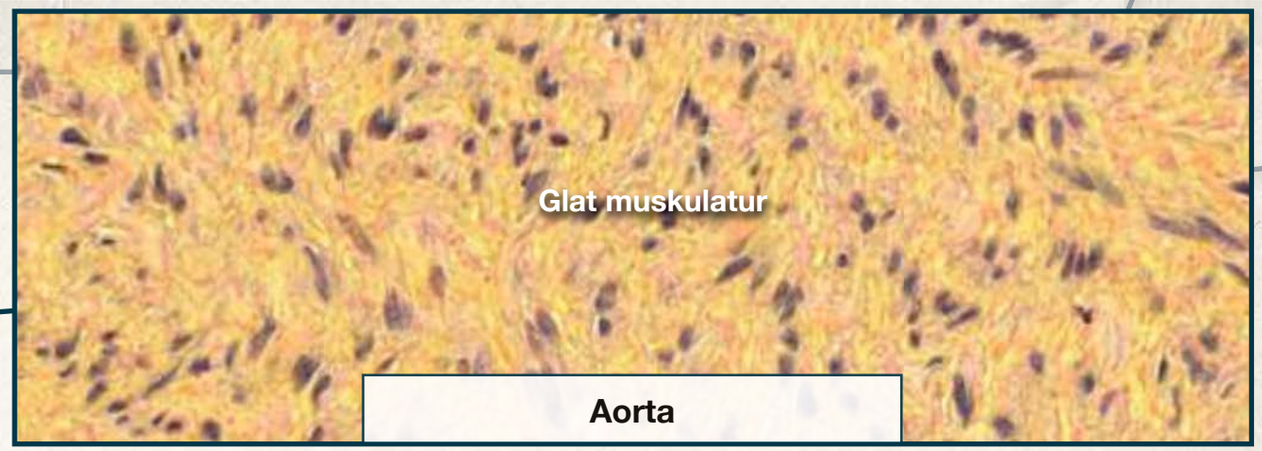

Aorta

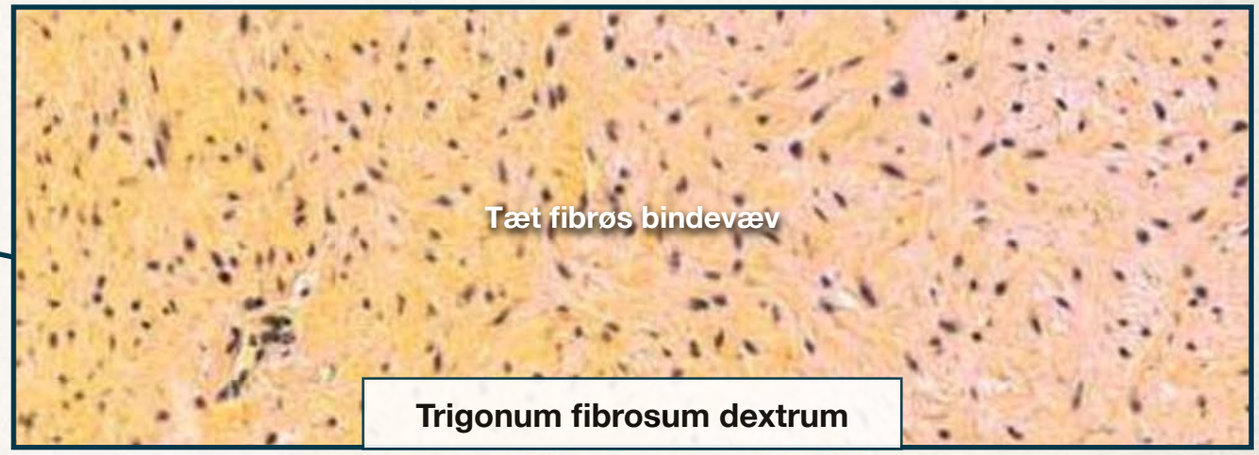

Trigonum fibrosum dextrum

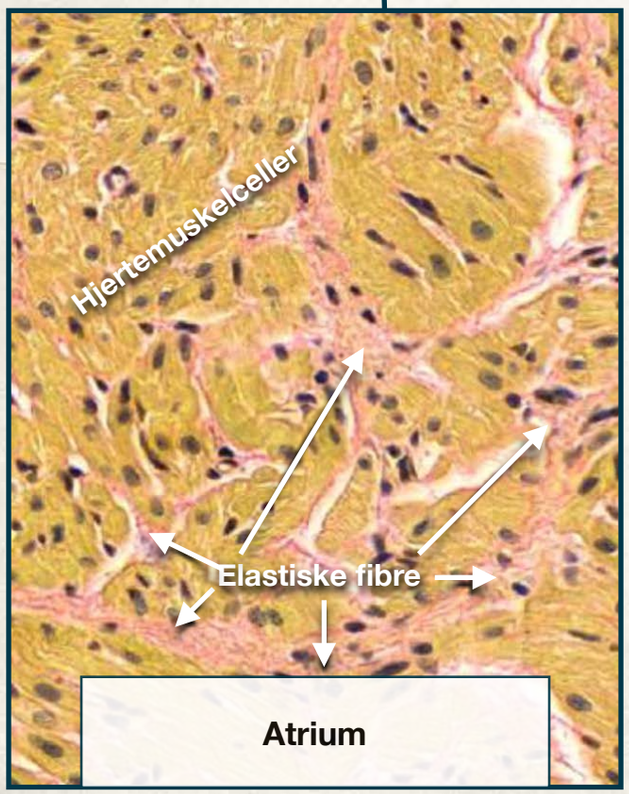

Atrium

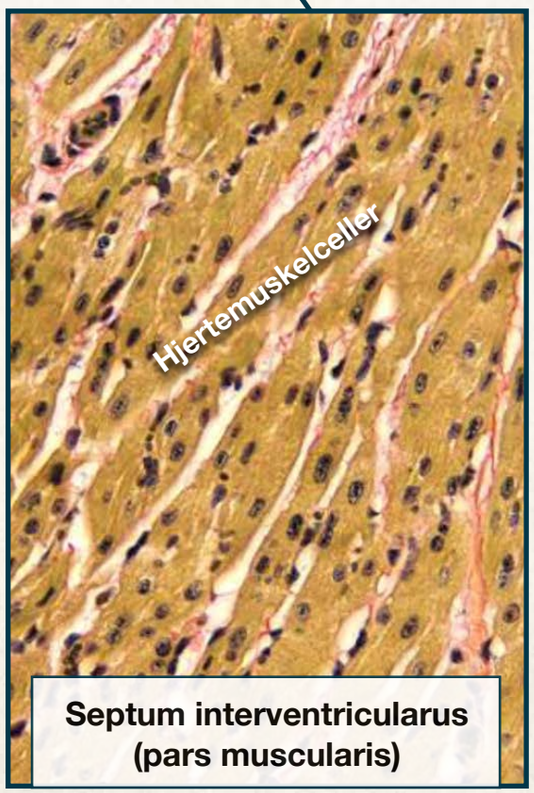

Septum interventricularus (pars muscularis)

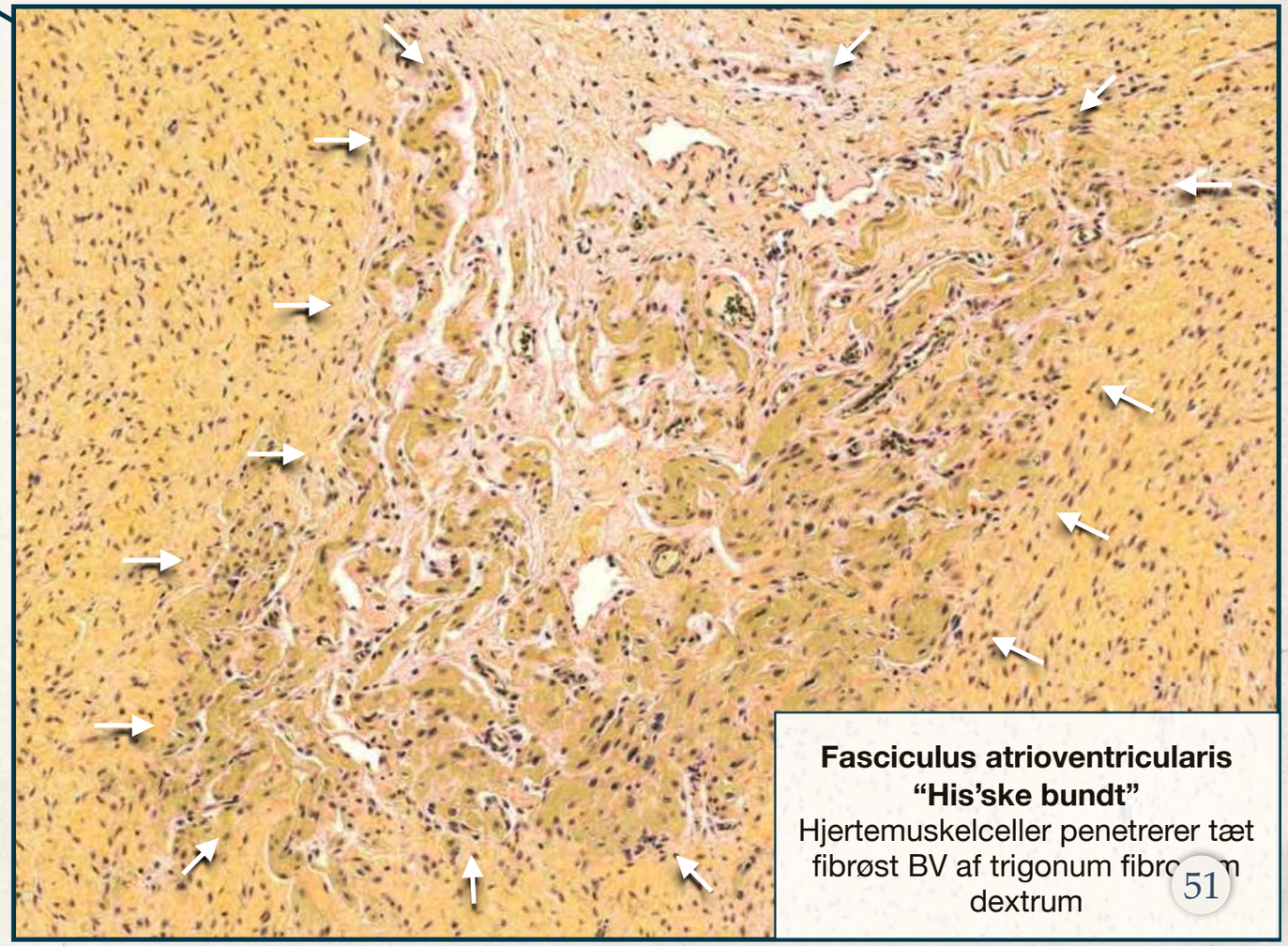

Fasciculus atrioventricularis "His'ske bundt"
Hjertemuskelceller penetrerer tæt fibrøst BV af trigonum fibrosum dextrum

MIKROSKOPISK SPOTGUIDE

Luftvejene & Lungerne

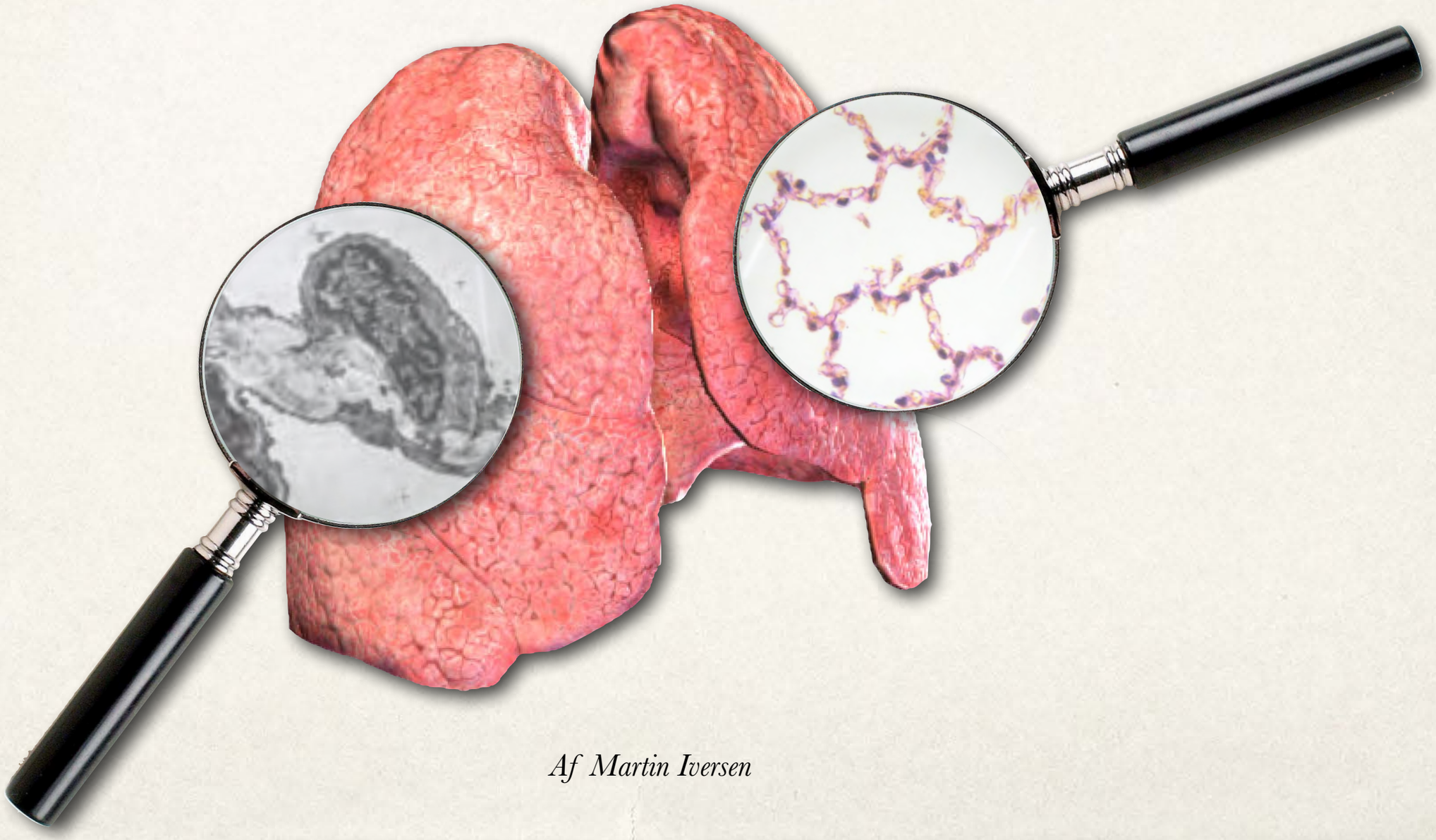

Af Martin Iversen

40. Ala nasi

Hæmatoxylin-Eosin



BMI | Kasse 48 | Præp. 40

41. Cavum nasi, Regio respiratoria

Hæmatoxylin-Eosin

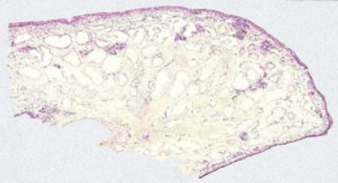

BMI | Kasse 48 | Præp. 41

41A. Epiglottis

Orcein

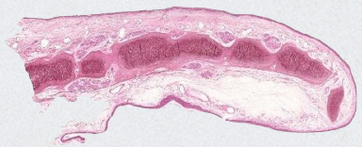

BMI | Kasse 48 | Præp. 35

42. Trachea

Alcianblå
PAS

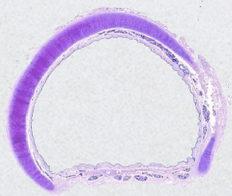

BMI | Kasse 48 | Præp. 42

43. Bronchie +Antrakotisk lymfeknude

Hæmatoxylin-Eosin

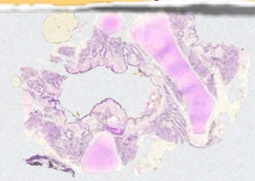

BMI | Kasse 48 | Præp. 43

43A. Lunge

PAS

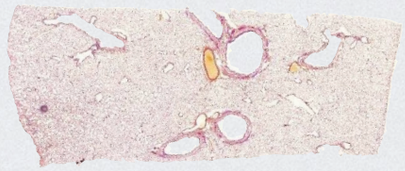

BMI | Kasse 36 | Præp. 43A

44. Lunge, Rotte Perf.fixeret

Hæmatoxylin-Eosin

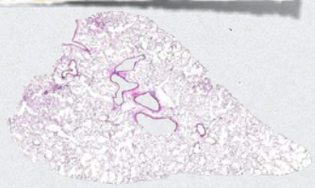

BMI | Kasse: 48 | Præp. nr: 44

45. Bronchie + Lunge, Gris

PAS

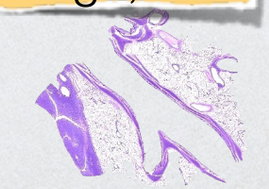

BMI | Kasse 48 | Præp. 46A

Hæmatoxylin Eosin

40. Ala nasi

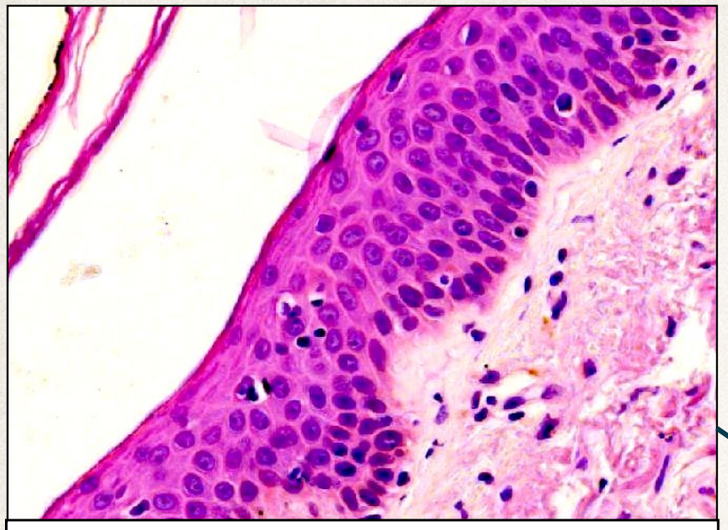

Alm. hud (flerlaget plade med forhorning)

Hårfollikel (vibrissae) samt talgkirtel



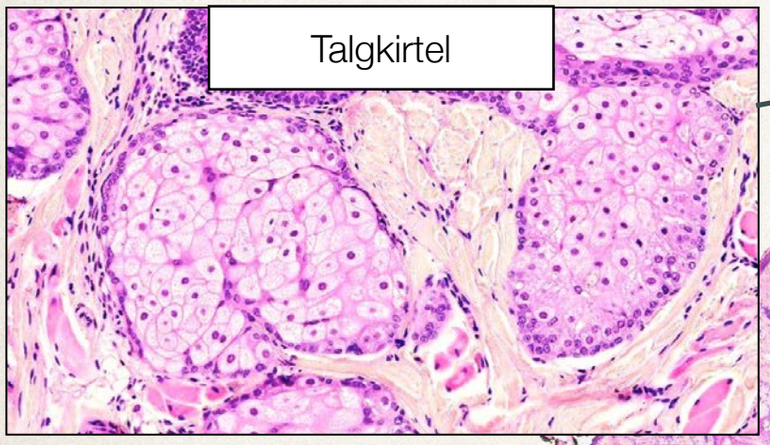

Talgkirtel

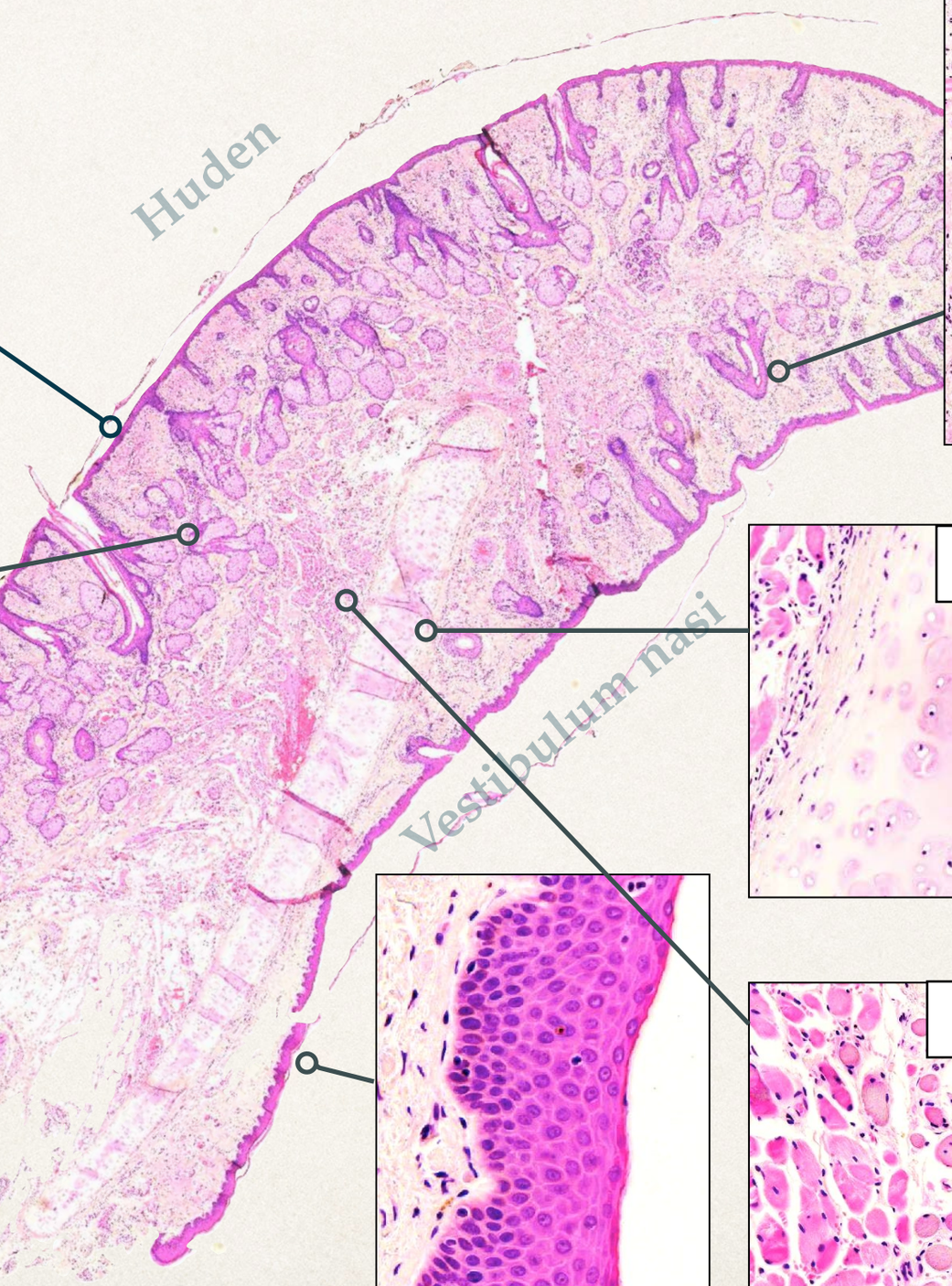

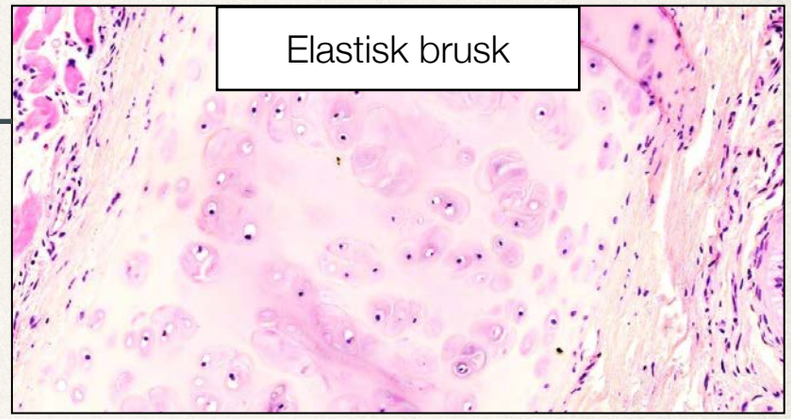

Elastisk brusk

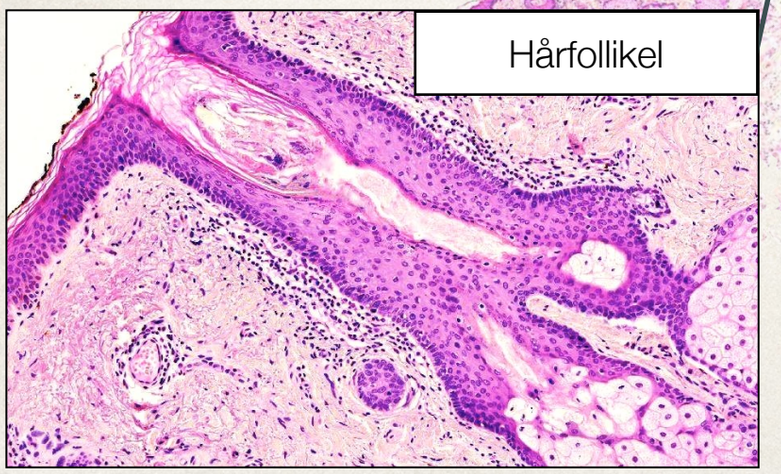

Hårfollikel

Flerlaget pladeepithel (vestibulum)

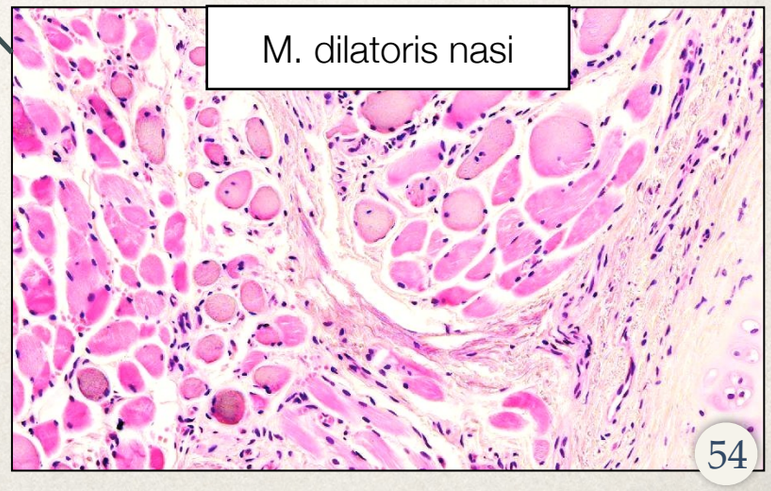

M. dilatoris nasi

Hæmatoxylin Eosin

41. Cavum nasi, Regio respiratoria

Cavum nasi

Se dette præparater på virmik's hjemmeside for luftvejsepithel i regio olfactoria.

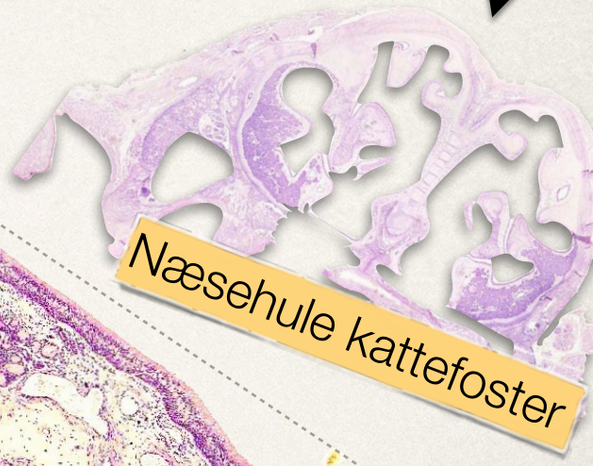

Pseudolagdelt cylinderepithel med cilier

Bægerceller

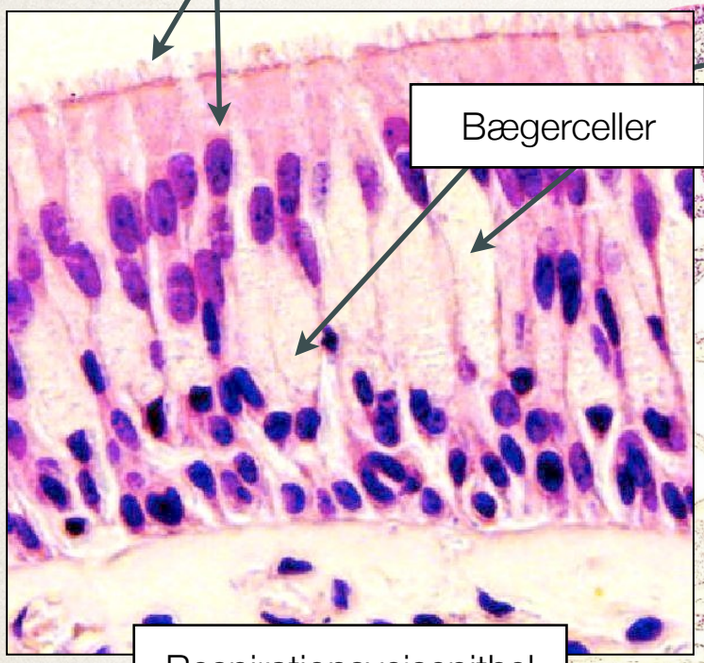

Respirationsvejsepithel

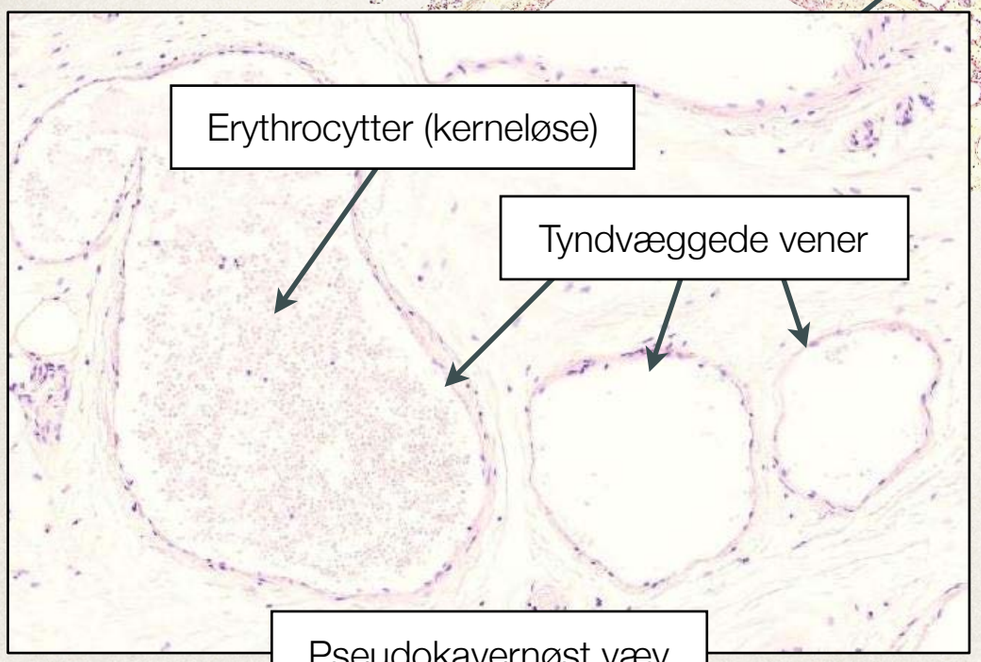

Erythrocytter (kerneløse)

Tyndvæggede vener

Pseudokavernøst væv

Muko-serøst kirtelendestykke

Von Ebnersk halvmåne

Udførselsgang

Muko-serøs kirtel

Orcein

41A. Epiglottis

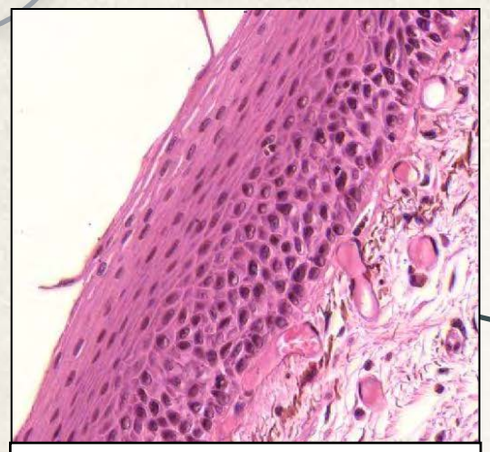

Flerlaget pladeepithel

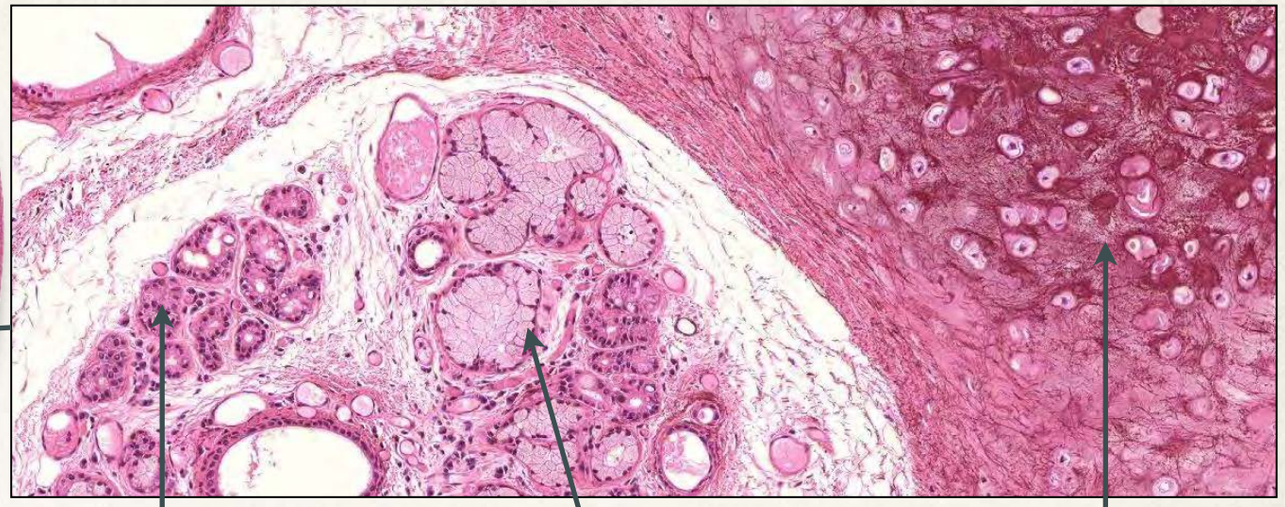

Serøse endestykker

Mukøse endestykker

Elastisk brusk

Larynx

Cavum oris

Ciliært pseudolagdelt cylinderepithel

Laryngeal overflade (”bagsiden”)
÷ tela submucosa

Lingual overflade (”forsiden”)
+ tela submucosa

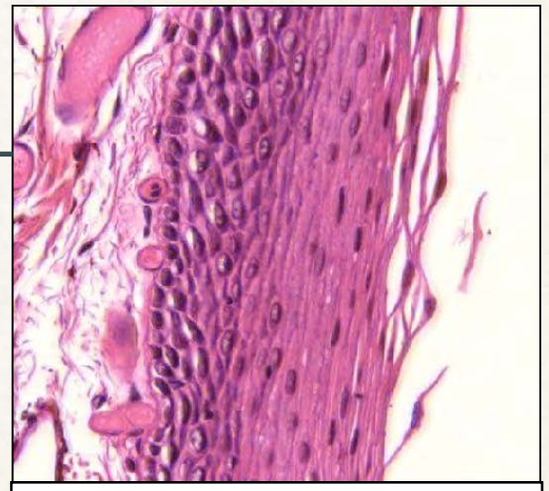

Flerlaget pladeepithel

Alcianblå PAS

42. Trachea

Fibroelastisk membran og tyk perichondrium

Adventitia

M. trachealis

Lumen

Anterior

Posterior

Muko-serøse kirtler

Hyalinbrusk

Tela submucosa

Lamina propria

Ciliært pseudolagdelt cylinderepithel med bægerceller (og børstesøm)

Tyk basalmembran

Hæmatoxylin Eosin

43. Bronchie +Antrakotisk lymfeknude

Blodkar

Stor udførselsgang

Brusk

Lumen

Brusk

Antrakotisk lymfeknude

Pseudolagdelt cylinderepithel med cilier og bægerceller

Artefakt i lumen

Tunica muscularis

Muko-serøst endestykke med Von-Ebnersk halvmåne

PAS **43A.** Lunge

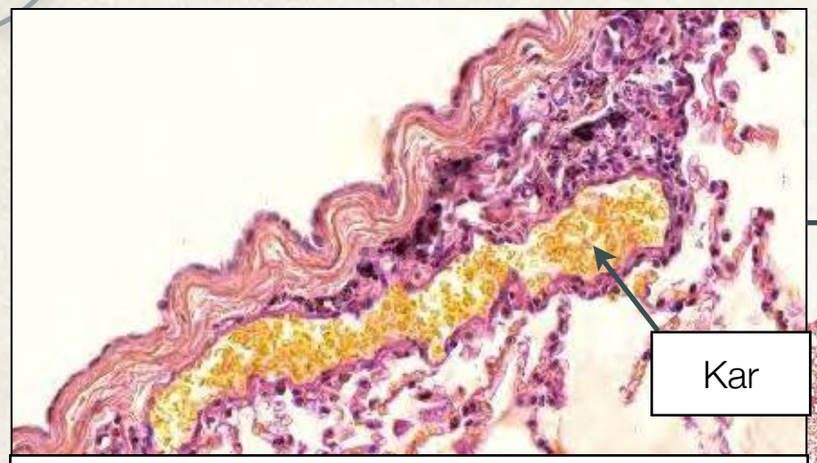

Kar

Pleura
(Mesothel og submesothelialt bindevæv)

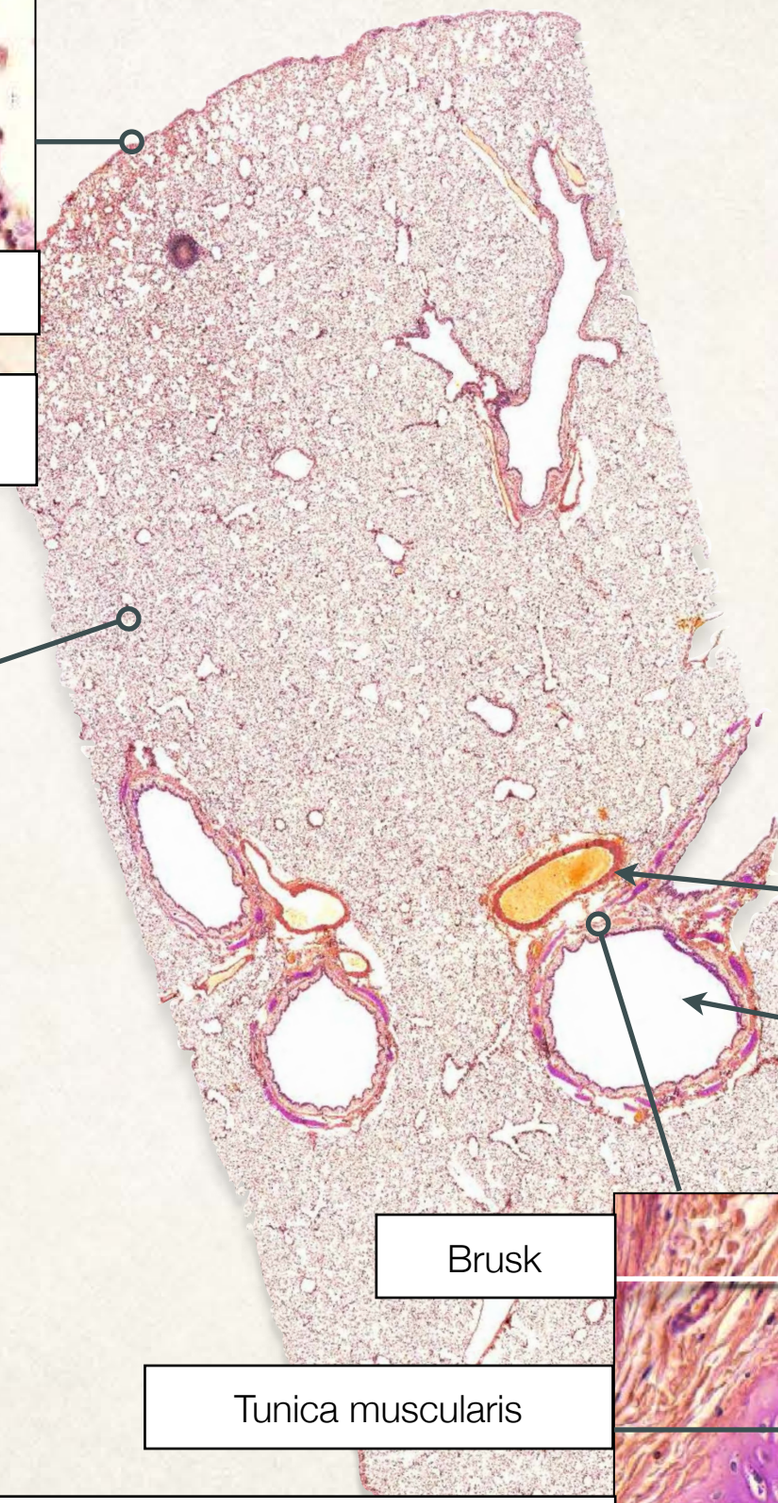

Alveole

A. pulmonalis gren

Bronchus

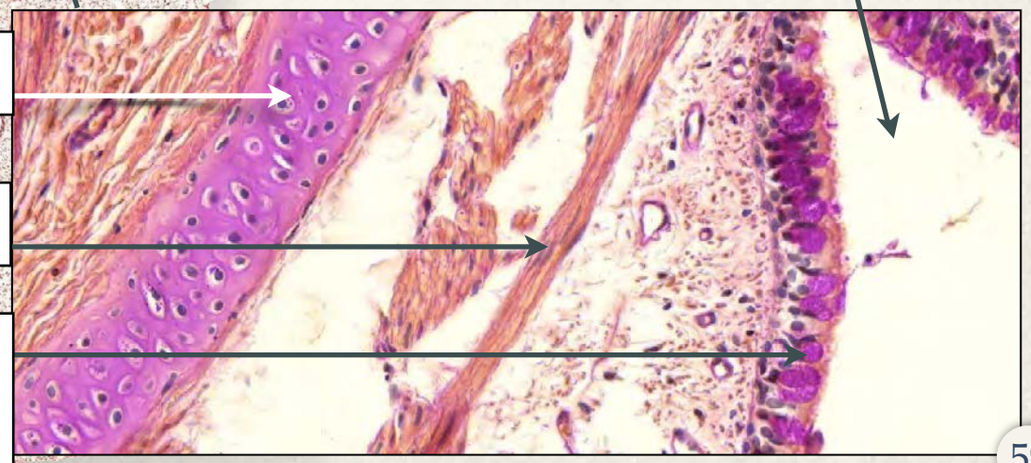

Brusk

Tunica muscularis

Pseudolagdelt cylinderepithel med cilier og bægerceller

Hæmatoxylin Eosin

44. Lunge, Rotte Perf.fixeret

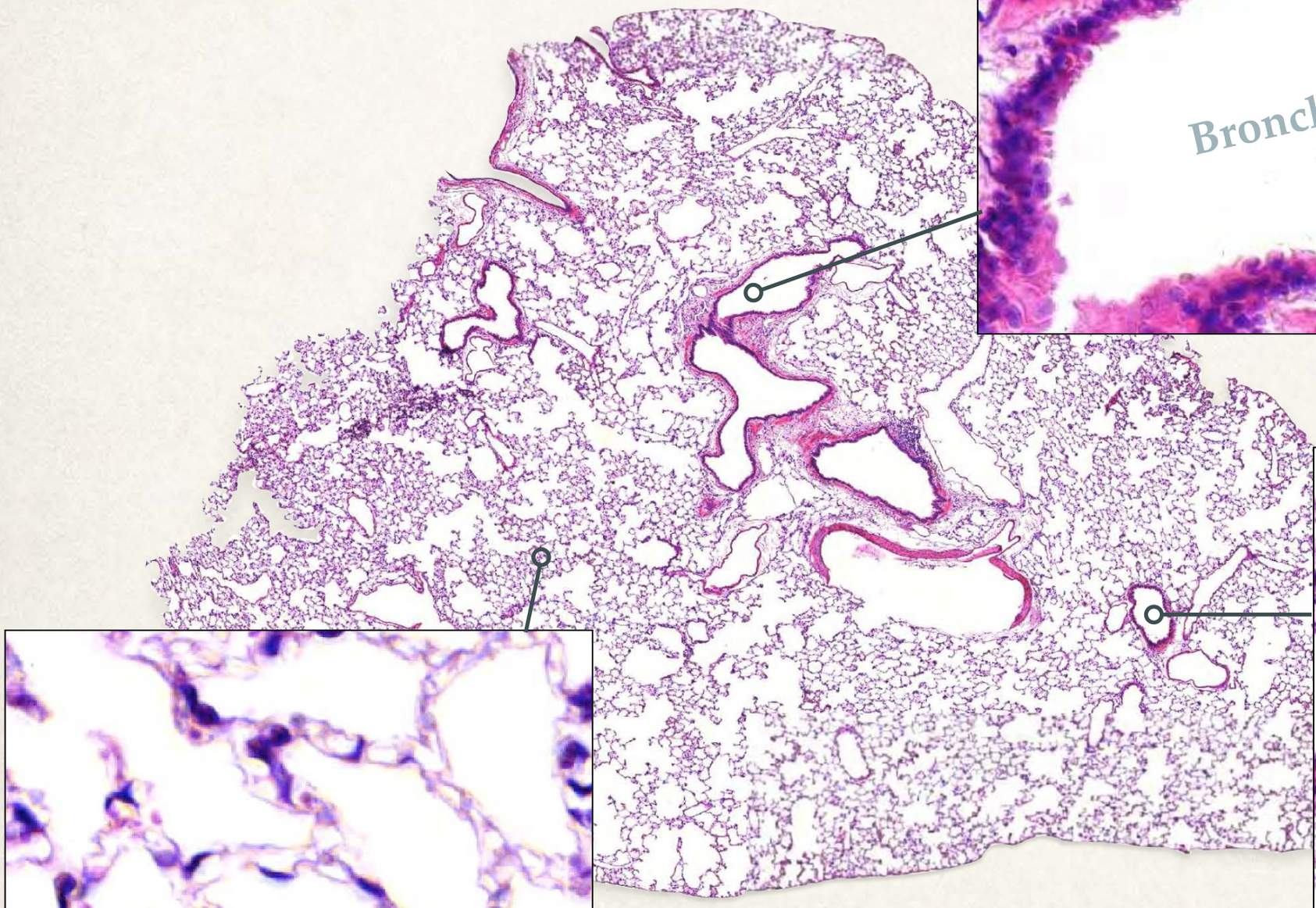

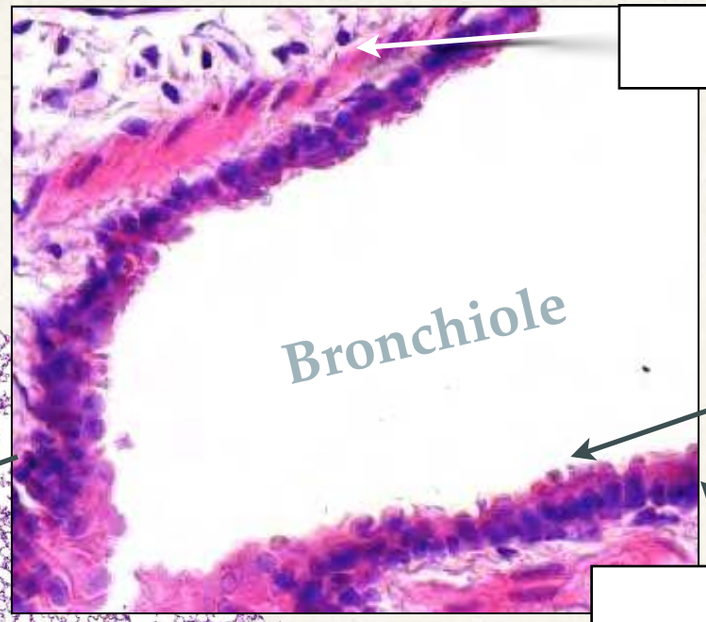

Tunica muscularis



Claracelle

Enlaget cylinderepithel

Alveoler

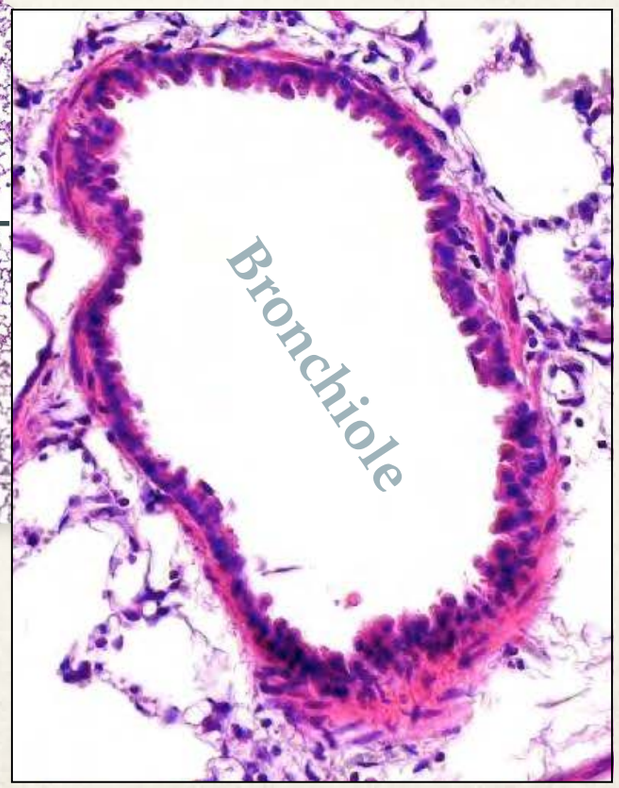

45. Bronchie + Lunge, Gris

PAS

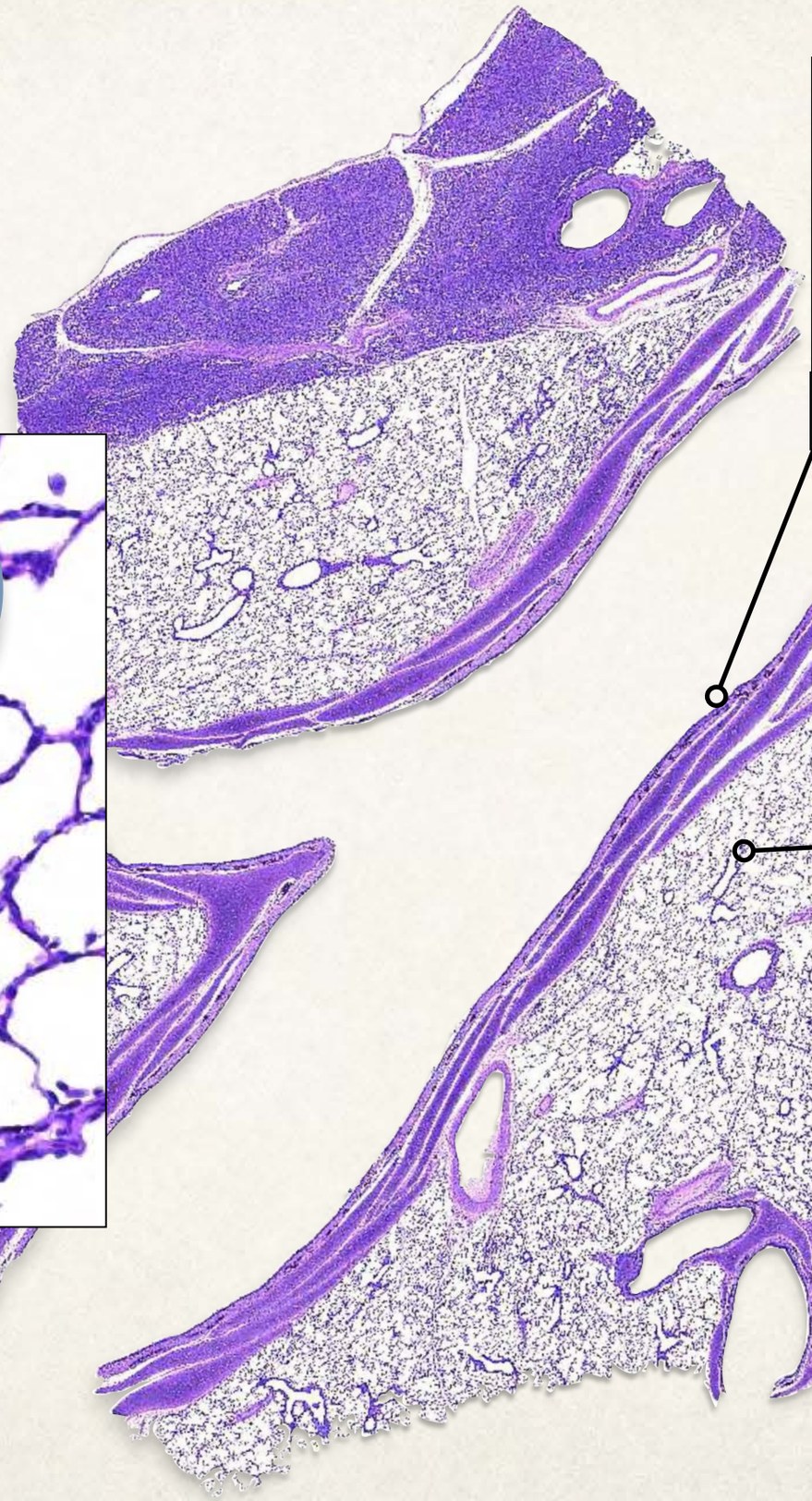

Saccus

Alveole

Atrium

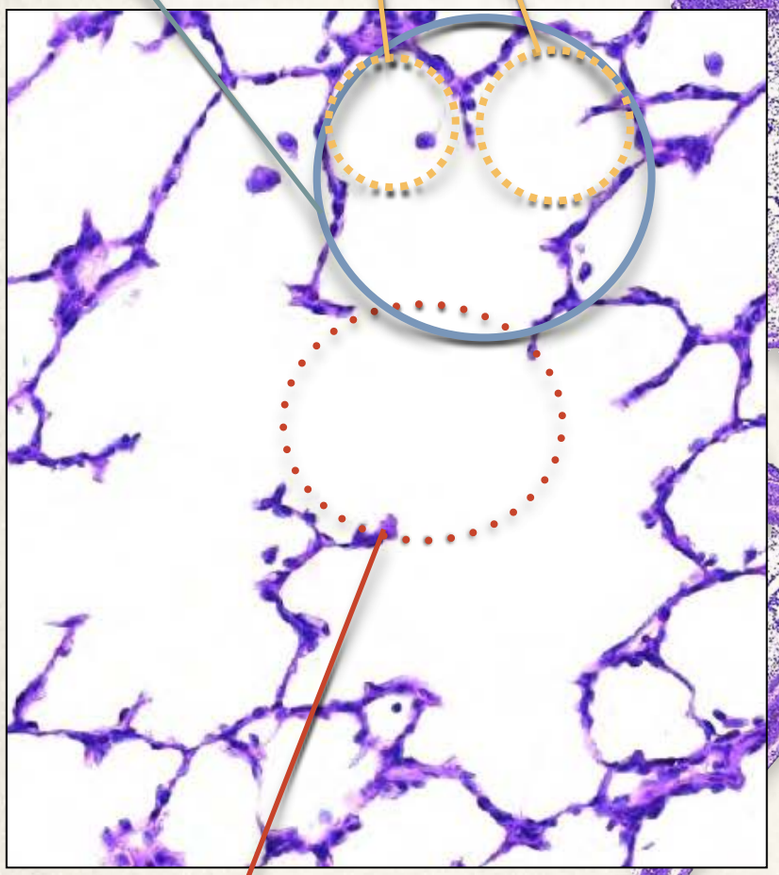

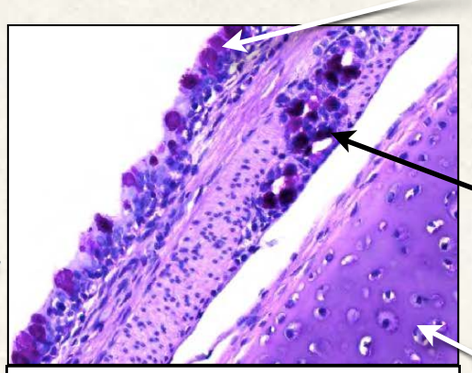

Pseudolagdelt cylinderepithel med cilier og bægerceller

Muko-serøst kirtelvæv

Hyalinbrusk

Stor bronchus

Alveole

Respiratorisk bronchiole

Terminal bronchiole

